

Prenatal and early postnatal development of the skull in Nigerian breeds of sheep: a gross anatomical study

¹Atabo S.M., ²Umar A.A., ^{1,2}Shehu S.A., ³Abubakar A.A., ²Bello A., ⁴Oyelowo, F.O. & ³Bodinga H.A.

¹Department of Veterinary Anatomy, Bayero University, Kano, ²Department of Veterinary Anatomy, Usmanu Danfodiyo University, Sokoto, ³Department of Veterinary Surgery and Radiology, Usmanu Danfodiyo University, Sokoto, ⁴Department of Veterinary Anatomy, University of Abuja, FCT, Nigeria.

*Corresponding author: smatabo.van@buk.edu.ng, +2348069728062

ABSTRACT

The aim of this study was to bridge the gap of information on the gross morphology of the skull of sheep foetuses. A total of 240 samples consisting of fetal and day-old Balami, Uda and Yankasa breeds were used; the skulls were prepared using chemical maceration technique. In the 1st trimester, no visible ossifications were observed on the skull. In the 2nd trimester, ossification of the frontal, parietal, occipital and basisphenoid bones were observed. The nasal bones were ossified, but concaved in Balami and flat in Uda and Yankasa. In the 3rd trimester, an interparietal bone developed between the parietal and occipital bones. The paracondyloid processes, occipital squamous, and the external occipital protuberance were developed in the 3rd trimester. The interparietal bone appeared paired in Yankasa but unpaired in Balami and Uda, which developed into a paired bone in the day-old. In the day-old, the orbital walls were completely fused except in the Uda; the formation of the cornual process began; the presphenoid of the Yankasa was developed. It was concluded that grossly, ossification was observed in the 2nd trimester and it began with the neurocranial bones, however, in the 2nd trimester, the skull was partly soft and pliable and the foramina were rudimentary. In the 3rd trimester, the skull bones were hard and osseous. All the bones on the dorsal surfaces of the skull were membranous whereas some of the bones of the ventral surface were cartilaginous in origin.

Keywords: Balami, interparietal, skull, Uda, Yankasa.

INTRODUCTION

Balami, Uda and Yankasa are three most common indigenous breeds of sheep in Nigeria (Popoola & Oseni, 2018). Balami breed is the largest bodied sheep in Nigeria. It is predominantly white and hairy, with a convex face. (Popoola & Oseni, 2018). The Uda breed is large but slightly smaller than the Balami. The Uda is long-legged with a convex face, the breed has a characteristic coat-colour pattern (Abdulmojeed & Isa, 2011). The anterior (fore) half is black or brown while the posterior (rear) half is white (Abdulmojeed & Isa, 2011), the Yankasa breed is intermediate in size. It has a typical white coat-colour with dwarf patches around the eyes, ears, muzzle and sometimes feet (Yakubu & Akinyemi, 2010).

Skull forms the skeleton of the head and it is the most important complexly organized group of bones (cranial and facial bones) (Dyce *et al.*, 2010). It is a flat bone which is relatively thin and expanded in two dimensions. The skull protects the brain and the organs of special senses (sight, smell, hearing, equilibrium, and taste) and provides the openings for the passages of air and food and houses the teeth for mastication in the jaws (Dyce *et al.*, 2010). The phenotypic appearance of the head of animal species depends strongly on the shape of the skull (Getty, 1975). The skull has also been used as a major skeletal structure to determine taxonomic affiliations as it is subjected to phenotypic changes because of selective breeding. The skull consists of several bones including the occipital bone which

is frequently studied in procedures of sex determination in forensics or anthropology (Bruenner *et al.*, 2002). The skull also consists of several foramina through which nerves from the brain emanate. The most notable of these foramina include foramen magnum, infraorbital, supraorbital, mental and mandibular foramina which are of great interest in scientific investigations due to their morphological variability and clinical application in regional anesthesia of the head (Janeczek *et al.*, 2011). Several studies have been conducted on the skull osteometry and morphology of different postnatal/adult breeds of sheep, however, there is little or no information on their foetal skull developmental morphology.

MATERIALS AND METHODS

This study was approved by Institutional Animal Care and Use Committee of Usman Danfodiyo University Sokoto reference no. UDUS/FAREC/2019/AUP-RO-17. A total of two hundred and forty (240) foetal samples (40 each of Balami, Uda and Yankasa) and day-old (40 each of Balami, Uda and Yankasa), these foetal and day-old samples were wasted fetuses obtained from slaughtered pregnant ewes in the abattoir (Table I).

Table I: Number of samples collected per breed of sheep across the age groups

S/N	Age	Balami	Uda	Yankasa	Total
1	1 st trimester	20	20	20	60
2	2 nd trimester	20	20	20	60
3	3 rd trimester	20	20	20	60
4	Day old	20	20	20	60
Total		40	40	40	240

PRENATAL SAMPLE PREPARATION

Their crown vertebral rump length (CVRL) were measured with a measuring tape (Butterfly®), extending from the anterior fontanel and following the vertebral column down to the base of the tail to determine the gestational ages in days using the formula: $X=2.1(Y+17)$ where X= Gestational Age in days and Y=Crown Vertebral Rump Length (Arthur *et al.*, 1989). The fetuses were further grouped into 1st, 2nd and 3rd trimesters (Table I).

PREPARATION OF FOETAL DAY-OLD SKULL SAMPLES

The heads of the samples were decapitated at the occipito-atlantal joint, weighed (using compression spring balance AT-1422, sensitivity of 20 kg X 50g) and brains flushed out using water and spatula as described by Vimini *et al.* (1983). A scalpel blade, scissors, and forceps were used to remove the skin and muscles of the head. Chemical maceration technique was adopted in the skull preparation

using 20% potassium hydroxide (KOH) for 48 hours to remove attached muscle remnants.

RESULTS

NEUROCRANIUM OF THE 1ST AND SECOND TRIMESTER FOETUSES

The findings were consistent in all breeds except where otherwise stated. In the 1st trimester, the skull was soft and pliable with no grossly visible ossification. In the 2nd trimester, the developing occipital bone was soft and pliable except at the left and right occipital condyles and occipital basilar which were hard and osseous. The basilar part was largely cartilaginous but ossified at the center; its rostral and caudal muscular tubercles were rudimentary and cartilaginous. The occipital squama, external occipital protuberance, median crest, and paracondyloid processes were not ossified, but appeared as flat soft and pliable mesenchymal connective tissues. The tympanic bulla had begun to appear in Uda but remained rudimentary in Yankasa, however, the rostral (styli form) processes of the tympanic bulla were yet to develop in both Uda and Yankasa. The interparietal bone was a soft mesenchymal tissue (Figures I and II).

The frontal and parietal bones that formed the dorsum of the skull were ossified, but the caudal end of the frontal bone together with the parietal bone was soft, flabby, and pliable, while the rostral end was hard and ossified. A stereomicroscope and rudimentary supraorbital foramen was present on the dorsal surface of the frontal bone, its canal was yet to develop. The opening of the supraorbital canal and the ethmoid foramen on the orbital wall of the frontal bone were absent. The frontal bones that formed the wall of the orbit were yet to ossify. Complete ossification and articulation of the frontal process of zygomatic bone (FPz) and the zygomatic process of frontal bone (ZPf) were yet to occur (Figures I and II).

The two parts of the temporal bone; the petrous and squamous parts were ossified, undifferentiated and existed as a single bone, the articular process of the temporal bone was flat, the temporal process of zygomatic bone was ossified, hard, its articular process was flat and articulated with the ossified zygomatic process of the temporal bone, but the temporal crest was rudimentary. The temporal margin of the orbit was incomplete and the mastoid foramen was yet to develop (Figures I and II).

The basilar part of the occipital bone articulated with the basisphenoid rostrally. The basisphenoid bone was ossified, hard, and fused with the occipital basilar, while the presphenoid was yet to ossify. The basisphenoid and presphenoid wings which formed part of the wall of the orbit were made of a thin, transparent and membranous structure. The sphenopalatine, optic, and oval foramina were

absent, but the foramen orbitotundum was present and conveyed nervous tissues. The pterygoid process of the basisphenoid was yet to ossify. The external surface of the basisphenoid was smooth and the median ridge was not developed (Figure VII).

The horizontal part of the ethmoid was present, observed as a hard, osseous structure; the cribriform was undeveloped, and the Cristal galli that divided the ethmoid into two halves (Figure III).

NEUROCRANIUM OF THE THIRD TRIMESTER FOETUSES

In the 3rd trimester, a hard, ossified, roughly triangular-shaped interparietal bone developed between the parietal and occipital bones. However, in the Yankasa, the interparietal bone was divided into two halves by an

interparietal suture, but in the Uda and Yankasa it appeared as a single bone. At this age, two new sutures appeared; the interparietoparietal suture and the interparieto-occipital suture. The paracondyloid processes, occipital squamous and the external occipital protuberance were developed, however, the nuchal and medial crest of the occipital bone were rudimentary. The occipital was made of hard osseous structure, a suture (occipital suture) distinguishing the occipital condyle and occipital squamous was visible. The cartilaginous basilar part was ossified, flat, and the caudal and rostral muscular tubercles were absent. The tympanic bulla was ossified, but it had a wide and semi-ovoid opening on its left and right lateral surfaces (Figures III and IV).

The entire frontal and parietal bones were hard and ossified. Vascular grooves were present on the dorsal surfaces of the

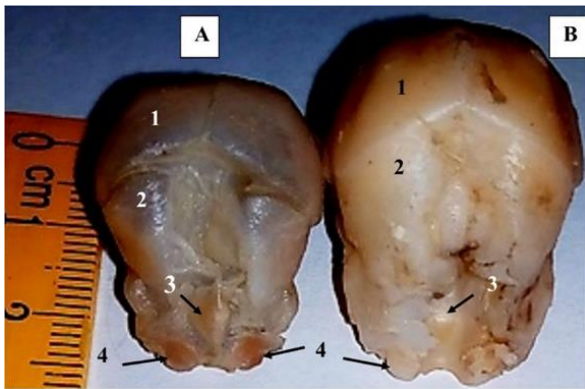

Figure I: Nuchal view of the Uda (A) and Yankasa (B) foetus at 2nd trimester, showing; the frontal bone (1), parietal bone (2), occipital bone (3), and occipital condyle (4)

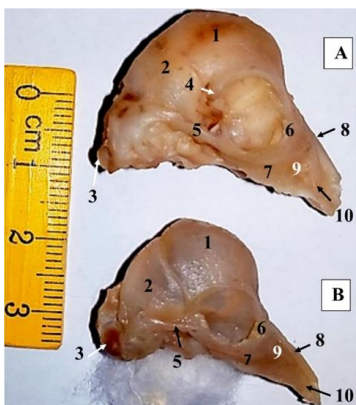


Figure II: Lateral view of the skull of the Uda (A) and Yankasa (B) breed at 2nd trimester, showing; the frontal bone (1), parietal bone (2), occipital condyle (3), zygomatic process of frontal bone (4), zygomatic arch (5), lacrimal bone (6), zygomatic bone (7), nasal bone (8), maxilla bone (9), and premaxilla bone (10)

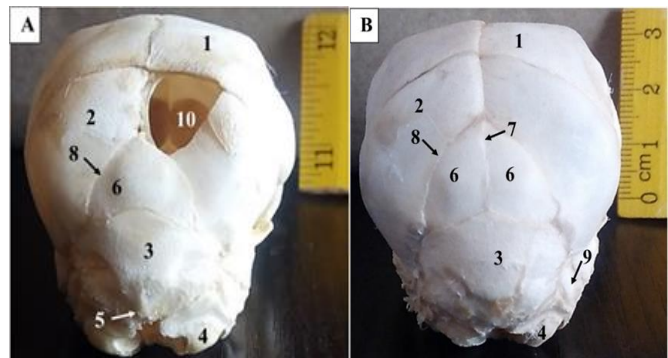


Figure III: 3rd trimester nuchal view of the Uda (A) and Yankasa (B) foetus showing; the frontal bone (1), parietal bone (2), occipital bone (3), occipital condyle (4), interparietal bone (6), interparietal suture (7), interparietoparietal suture (8), mastoid process (9), and membranous cribriform plate (10)

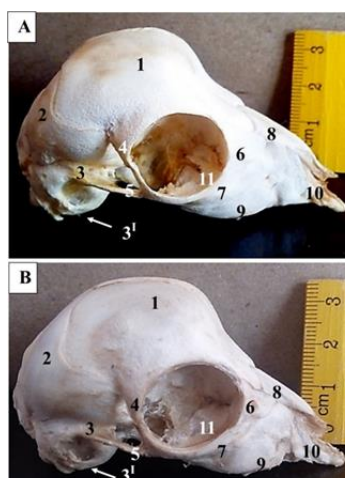


Figure IV: 3rd trimester lateral view of the skull of the Uda (A) and Yankasa (B) breed showing; the frontal bone (1), parietal bone (2), temporal bone (3), tympanic bulla (3'), zygomatic process of frontal bone (4), zygomatic arch (5), lacrimal bone (6), zygomatic bone (7), nasal bone (8), maxilla bone (9), premaxilla bone (10), and lacrimal bulla (11)

frontal bone radiating from its ossification centres and the supraorbital foramina and supraorbital canal were developed and grossly visible with nerves passing through them. The frontal bone that forms part of the orbital wall had ossified, except at the caudal part of the orbit. The openings of the supraorbital canal and the ethmoid foramen on the orbital wall were present but rudimentary, complete ossification, and partial articulation of the frontal process of zygomatic and the zygomatic process of frontal bone occurred (Figures III and IV).

The temporal bone was differentiated into two parts (the squamous and petrous parts). The squamous part consisted of the body and a zygomatic process, the temporal crest of the zygomatic process and the temporal margin of the orbital wall were developed. The petrous part consisted of the tympanic bulla and mastoid process, but its mastoid foramen, external auditory meatus, and internal auditory meatus were yet to develop; the caudal end of the tympanic bulla was yet to ossify (Figures III and IV).

The presphenoid was still membranous in Yankasa but ossified in Uda, the basisphenoid and presphenoid wings were ossified, the optic and oval foramina were patent, but the sphenopalatine foramen was still absent. The median ridge on the external surface of the basisphenoid began to develop and occupy only the caudal $\frac{1}{3}$ of its length (Figure VIII). The cribriform was not developed and the ethmoid foramen was still absent.

NEUROCRANIUM OF THE DAY-OLD

In the day old, the single interparietal bone in the Uda was observed to have divided into two halves as in the 3rd trimester Yankasa breed, the median and nuchal crest had developed in both breeds and the caudal muscular tubercles of the basilar part was developed in Uda but absent in Yankasa (Figures V and IV).

In the Yankasa breed of sheep, a roughly circular bone was seen developing at the junction of the anterior fontanel between the frontal and parietal bones (Figure V), the vascular grooves of the frontal bone were present. The orbital walls formed by the frontal bones were completely fused except for the Uda breed where a small part at the caudodorsal aspect of the bone was yet to ossify. Complete articulation of the frontal process of zygomatic and the zygomatic process of frontal bones occurred. A small stump was observed projecting from the caudolateral walls of the frontal bones to mark the beginning of the formation of the cornual process (Figure VI).

The mastoid foramen and internal auditory meatus were developed, however, the osseous structure that forms the external auditory meatus was not visible and the area was covered by a thin membranous sheath. This ossification of the caudal end of tympanic bulla progressed but still

incomplete, leaving an external opening on the tympanic bulla (Figures V and VI).

The presphenoid of the Yankasa was developed, the sphenopalatine foramen was not visible, and the median ridge became well developed, sharp and extended throughout the medial length of the presphenoid (Figure IX). The cribriform was developed and demarcated the nasal cavity from the neurocranial cavity, ethmoid foramen was also developed and was observed on the orbital wall of the frontal bone (Figures VI).

VISCEROCRANIUM

In the 2nd trimester, the lacrimal crest appeared in the Uda, but rudimentary and in some cases not visible in Yankasa, the foramen of the lacrimal bone was not developed (Figures II and X). The foramen appeared in the 3rd trimester and was more prominent in Uda. In the day old, no further development of lacrimal crest was noted in the Yankasa, but it was well developed in Uda (Figures VI and XII). In the 2nd, 3rd trimesters and day old, the nasal bones were ossified across their full length, the left and right parts were firmly attached and articulated caudally with the frontal bones (Figures II – VI and X – XII). The rostral end curved ventrally in Uda, but flat in Yankasa. In the 2nd trimester, the infraorbital foramen of the maxilla was not grossly visible, the alveolus of the maxilla of the upper cheek teeth was developed and opened. In the 3rd trimester, the infraorbital foramen was well developed and grossly visible, the 2nd and 3rd premolar and the 1st and 2nd molar began to erupt within the alveolus. In the day old, these teeth erupted above the alveolus into the buccal cavity. In the 2nd, 3rd trimesters and day-old the palatine fissures of premaxilla were present but tiny, the palatine process of the premaxilla extends caudally to articulate with the palatine bone, the palatine process articulated with the palatine bone at the maxillopalatine suture. Across the three age groups, the major palatine foramen was observed and a chronological increase in its size was noted, however, the minor palatine foramen was not visible (Figures VII - IX). The horizontal and perpendicular palatine bone and the sphenopalatine fossa were present. In the 2nd trimester, the pterygoid bone and hamulus were not developed. In the 3rd trimester and day old, the pterygoid together with its hamulus were developed, the hamulus was hook-like and projected caudally. In the 2nd trimester, the vomer and turbinates bones were yet to ossify. In the 3rd trimester and day old, the vomer and turbinate bones began to ossify. The ossification of the vomer extended rostrocaudally and that of the turbinates extended caudorostrally (Figures VII - IX).

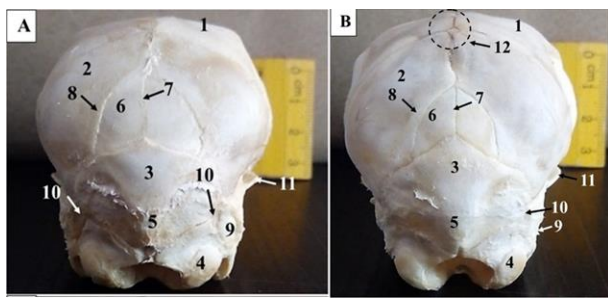


Figure IV. Day old nuchal view of the Uda (A) and Yankasa (B) foetus showing; the frontal bone (1), parietal bone (2), occipital bone (3), occipital condyle (4), external occipital protuberance (5), interparietal bone (6), interparietal suture (7), interparietoparietal suture (8), mastoid process (9), mastoid foramen (10),temporal crest (11), and circular bone (12)

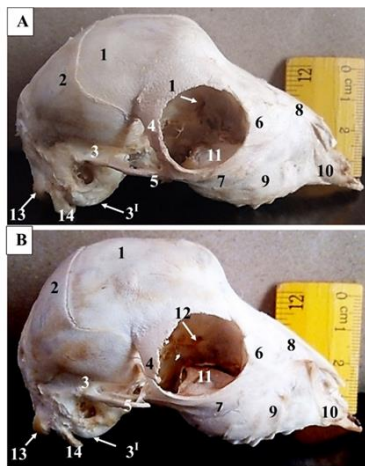


Figure VI. Day old basal view of the skull of the Uda (A) and Yankasa (B) breed showing; the occipital basilar (1), basisphenoid (2), presphenoid bone (3), palatine bone (4), maxilla bone (5), palatine fissure (6), major palatine foramen (7), perpendicular plate of palatine (8), upper cheek teeth (9), pterygoid process of basisphenoid bone (10), vomer bone (11), median ridge (12), and styliiform process (13)

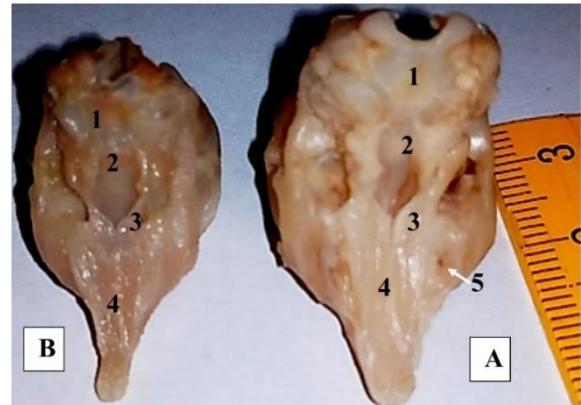


Figure VII. 2nd trimester basal view of the skull of the Uda (A) and Yankasa (B) foetuses showing; the occipital basilar (1), basisphenoid (2), palatine (3), palatine process of premaxilla (4), and maxilla alveoli opening (5)

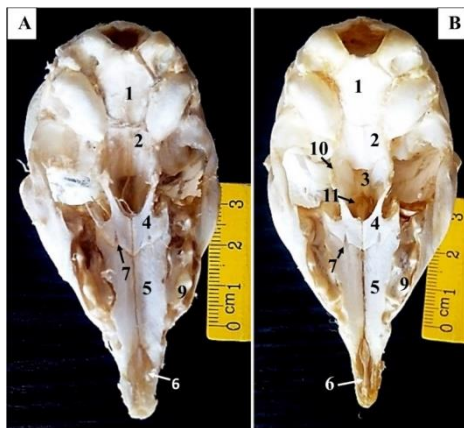


Figure VIII - 3rd trimester basal view of the skull of the Uda (A) and Yankasa (B) foetuses showing; the occipital basilar (1), basisphenoid (2), presphenoid bone (3), palatine bone (4), maxilla bone (5), palatine fissure (6), major palatine foramen (7), perpendicular plate of palatine (8), upper cheek teeth (9), pterygoid process of basisphenoid bone (10), and vomer bone (11)

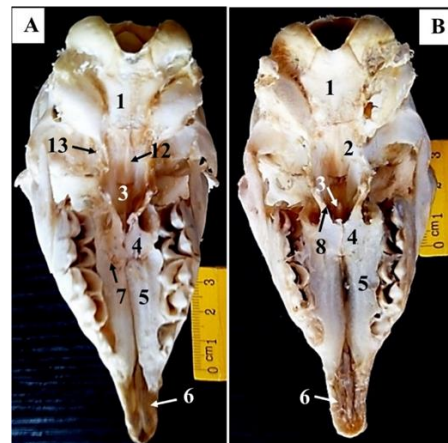


Figure IX. Day old basal view of the skull of the Uda (A) and Yankasa (B) breed showing; the occipital basilar (1), basisphenoid (2), presphenoid bone (3), palatine bone (4), maxilla bone (5), palatine fissure (6), major palatine foramen (7), perpendicular plate of palatine (8), upper cheek teeth (9), pterygoid process of basisphenoid bone (10), vomer bone (11), median ridge (12), and styliiform process (13)

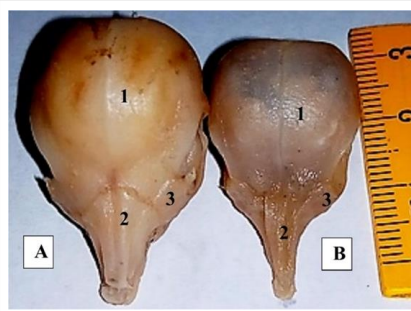


Figure X. 2nd trimester rostral view of the skull of the Uda (A) and Yankasa (B) fetuses showing; the frontal bone (1), nasal bone (2), and lacrimal bone (3)

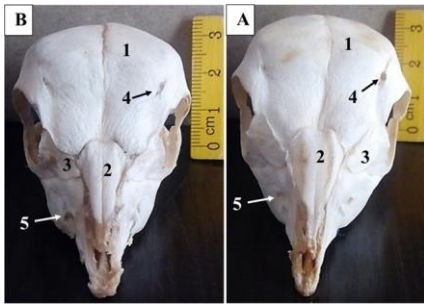


Figure XI. 3rd trimester rostral view of the skull of the Uda (A) and Yankasa (B) fetuses showing; the frontal bone (1), nasal bone (2), lacrimal bone (3), supraorbital foramen (4), and infraorbital foramen (5)

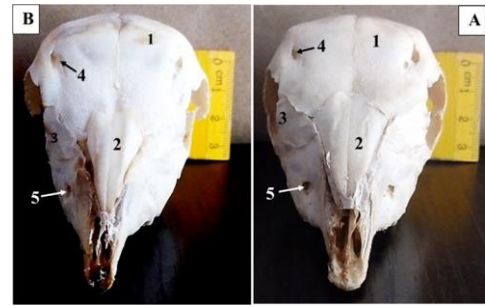


Figure XII. Day old rostral view of the skull of the Uda (A) and Yankasa (B) breeds showing; the frontal bone (1), nasal bone (2), lacrimal bone (3), supraorbital foramen (4), and infraorbital foramen (5)

DISCUSSION

The findings of the gross foetal craniomorphology of the Uda and Yankasa breed in this study revealed that the ossifying skull at the 2nd trimester was soft and pliable and relatively hard at the 3rd trimester, this may signify that there was an increase and rapid ossification of the skull bones between the 2nd and 3rd trimester fetuses, which agrees with the work of Hena and Sonfada (2012) in camel fetal calvaria. Generally, as the bones of the skull develop it undergoes different changes in shape before finally assuming its permanent shape. This is consistent with the work of Hassan *et al.* (2012). The different parts of the skull bones and foramina developed at a different pace, this implies that the time of development of the structures passing through the foramina may also differ. The foramina appeared faster in Yankasa than Uda, initially as a microscopic structure especially in the 2nd trimester, and they later became grossly evident in the 3rd trimester and day-old. However, the tympanic bulla appeared faster in Uda than in Yankasa, it was present from the 2nd, 3rd trimesters, and day-old as an ovoid structure with an incomplete caudal margin. This is similar to the work of Soanag (1996), who described the developing tympanic ring in Italian Bovine foetus as a circumscribed structure which is dorsally incomplete. In the Uda and Yankasa breeds, the interparietal bone was absent in the 2nd trimester and appeared in the 3rd trimester. These findings are in total disagreement with the work of Martín and García-Gonzalez (2015), who reported that the interparietal bone is not present during the fetal phase and that it formed at birth and fuses by day 20 in the Spanish breeds of sheep. The

emergence of the interparietal bone as two halves suggests two possible ossification centres. This is consistent with the work of Vanden Berg-Foels *et al.* (2006) in humans. A study on the interparietal bones in the Human skull by Yücel *et al.* (1998) revealed that only 2.8% of 500 skull samples had interparietal bones. The pattern of ossification of the neurocranial and viscerocranial bones observed in this study agrees with the work of Werneburg *et al.* (2015) although at varying age possibly due to breed/specie differences. The growth and development of the skull bones in humans are also influenced by nutritional and individual factors, the faster skull ossification noted in the sheep is probably because they become adults in a shorter time compared to humans (Vanden Berg-Foels *et al.*, 2006).

CONCLUSION

Ossification was observed in the 2nd trimester, and it began with the neurocranial bones, however, in the 2nd trimester, the skull was partly soft and pliable, and the foramina were rudimentary. In the 3rd trimester, the skull bones were hard and osseous, the foramina were prominent, and processes were developed. In all the age groups, the major and minor palatine foramina were present and absent respectively. The interparietal bone appeared prepartum and paired in Yankasa but unpaired in Balami and Uda, which developed into a paired bone in the day-old. All the bones on the dorsal surfaces of the skull were membranous whereas some of the bones of the ventral surface were cartilaginous in origin.

CONFLICT OF INTEREST

The authors declare that no conflict of interest exists.

REFERENCES

- Abdulmojeed, Y. & Isa, A.I. (2011). Multivariate analysis of morphostructural characteristics in Nigerian indigenous sheep. *Italian Journal of Animal Science*, 10(2), 83-86.
- Arthur, G.H, Noakes, D.E. & Pearson H. (1989). Veterinary reproduction and obstetrics. 6th ed. Bailliere. Tindall, London; p59.
- Bruenner, H., Lugon-Moulin, N., Ballaux, F., Fumagalli, L. & Hausser, J. (2002). A taxonomical reevaluation of the Valais chromosome race of the common shrew *Sorex araneus* (Insectivora: Soricidae). *Acta Theriogenology*, 47, 245 – 275.
- Dyce, K.M., Sack, W.O. & Wensing, C.J.G. (2010). Text book of Veterinary anatomy 4th edition Saunders Elsevier Inc. 3251 Riverport Lane St. Louis, Missouri 63043, 728-742.
- Getty, R. (1975). The Anatomy of the Domestic Animals, Vol. I, II, 5th edition,
- Hassan, H.E., Elamin, K.M., Yousif, I.A., Musa, A.M. & Elkhairey, M.A. (2012). Evaluation of Body Weight and some Morphometric Traits at Various Ages in Local Rabbits of Sudan. *Journal Animal Science Advances*, 2(4), 407-415.
- Hena, S.A. & Sonfada, M.L. (2012). Morphological Studies on the Prenatal Development of Calvaria in Dromedarian Camel. *Journal Animal Science Advances*, 2(6), 551-557.
- Hena, S.A. (2012). Developmental studies of the calvaria of one-humped camel (*Camelus dromedarius*) M.Sc. Dissertation, Department of Veterinary Anatomy, Usmanu Danfodiyo University Sokoto.
- Janeczek M., Chroszcz, A. & Czerski, A. (2011). Morphological Investigations of the Occipital Are in Adult American Staffordshire Terriers. *Anatomia Histologia Embryologia*, 40, 278–282.
- Martín, P. & García-Gonzalez, R. (2015). Identifying sheep (*Ovis aries*) fetal remains in archaeological contexts. *Journal of Archaeological Science*, 64, 77-87.
- Popoola, M.A. & Oseni, S.O. (2018). Multifactorial Discriminant Analysis of Cephalic Morphology of Indigenous Breeds of Sheep in Nigeria. *Slovak Journal of Animal Science*, 51(2), 45–51.
- Soanag, S., Bertongi, G., Gnudai, G. & Botti, P. (1996). Osteogenesis of the Fetal Bovine Skull. *Anatomia Histologia Embryologia*, 25, 167-173.
- Vanden Berg-Foels, W.S., Todhunter, R.J., Schwager, S.J. & Reeves, A.P. (2006). Effect of early postnatal body weight on femoral head ossification onset and hip osteoarthritis in a canine model of developmental dysplasia of the hip. *Pediatric Research*, 60, 549-54
- Werneburg, I., Polachowski, K.M. & Hutchinson, M.N. (2015). Bony skull development in the Argus monitor (*Varanus panoptes*) with comments on developmental timing and adult anatomy. *Zoology*, 118, 255–280
- Yakubu, A. & Akinyemi, M.O. (2010). An evaluation of sexual size dimorphism in Uda sheep using multifactorial discriminant analysis. *Acta Agriculturae Scandinavica*, 60, 74-78.
- Yücel, F., Egilmez, H. and Akgün, Z. (1998). A Study on the Interparietal Bone in Man. *Turkish Journal of Medical Sciences*. 28, 505-509.