

## Surgical management of dystocia in a three-yea-old *Lhasa apso* bitch: a case report

<sup>a\*</sup>Chibuogwu I. C., <sup>b</sup>Osemeka C. C., <sup>b</sup>Angyer, M., <sup>a</sup>Waziri M. A., <sup>a</sup>Ribadu A. Y

<sup>a</sup> Department of Theriogenology, Faculty of Veterinary Medicine, University of Abuja, Main Campus, Mohammed Maccido Road, Airport Road, PMB 117 Abuja, <sup>b</sup> Immunity Veterinary Clinic, No. 72 32<sup>nd</sup> Crescent, Gwarinpa Estate, Abuja 900108, FCT, Nigeria.

\*Correspondence: Ijeoma.chibuogwu@uniabuja.edu.ng, +234 803 694 3285

### ABSTRACT

In this case report, a Lhasa-apso bitch that experienced dystocia at term before the delivery of the first serial foetus was presented to the clinic. The bitch had been straining for over 24 hrs during which a clear-fluid vaginal discharge was observed about 2 hrs before presentation. Physical examination of the patient revealed a protruding membrane through the vagina and life foetuses proximal to a dead one. The history and findings of the physical examination guided the indication for an emergency caesarean section to save the life foetuses. The first foetus was mal-postured and died *in utero* but two life foetuses were delivered by caesarean section. The patient was subsequently spayed as requested by the owner. The post-surgery haemogram showed normochromic normocytic anaemia, lymphocytic leucocytosis, neutropenia and thrombocytopenia despite that the bitch was apparently healthy. A routine post-surgical three-day antibiotic cover, anti-inflammatory and haematinic were administered post-surgery. The patient was discharged three days post-surgery as all vital physiologic parameters were normal and puppies suckled normally. This case reaffirms the importance of history and proper clinical examination as guides for appropriate management of dystocia case. It also emphasises the need to interpret the haemogram of a dystocia patient in the context of the normal physiologic changes of a periparturient bitch. The haemogram was considered a normal finding in the circumstance of dystocia in the patient.

**Keywords:** Caesarean section, haemogram, ovariohysterectomy, foetal mal-posture

### INTRODUCTION

Dystocia is a condition of difficult, prolonged or abnormal labour. It may occur in any animal species. Pasch (2024) reported a dystocia prevalence of 21.2% in Purebred dogs of which 54% undergo caesarean section. Brachycephalic dog breeds like bulldogs, English Toy Spaniels, Japanese Chin, Pekingese, Pug and *Lhasa Apso* represent about 41% of dystocia cases. It is one of the most common obstetrical problems in dogs.

Normal labour (eutocia) in polytocous species, such as the dog, differs from labour in monotocous species. In monotocous species, an experience of the three stages of labour occurs in a stretch and the neonate is delivered. In polytocous species, the three stages of labour occur in episodes that represent the delivery of each foetus. Eutocia in polytocous species include Stage I labour which involves the onset of uterine contractions, progressive dilation of the cervix, drop in temperature, restlessness, nesting behaviour, panting, and anorexia. In Stage II labour, the foetus gets engaged to the cervix and Ferguson's reflex is initiated

which triggers strong uterine contraction. Then, the foetus is expelled through the vagina. The first puppy is expelled within 4 hrs of the onset of stage II labour. In stage III labour, the placentae are expelled. Labour becomes a dystocia in Stage I if it is not initiated at term', after a drop in temperature, or more than 24 hrs without progression to Stage II. In Stage II dystocia, vaginal delivery of the foetus does not occur within 1– 4 hrs of foetal engagement at the cervix, or a difficult parturition preceded a moribund or stillborn foetus, or more than 2 hrs elapsed between the delivery of successive foetuses, or there were no complete deliveries of all pups within 4–12 hrs. In stage III dystocia, the placentae are not expelled after one or more successful foetal deliveries. The causes of dystocia have been extensively studied and generally classified as maternal factors (Uterine inertia, pelvic canal anomalies), foetal factors (relative or absolute foetal oversize, malposition, malposture, and anomalies) and a mixture of maternal and foetal factors (secondary inertia which develops after one or more foetuses are delivered).

## HISTORY AND SIGNALMENT

On May 20, 2024, a pregnant 3-year-old multipara Lhaso Apso bitch weighing 8.0 kg was presented to Immunity Veterinary Clinic, Gwarinpa Abuja with the primary complaint of an uneventful straining and inability to whelp after more than 24 hrs of observation. The owner observed clear fluid discharge from the vagina more than 2 hrs before the presentation. The patient's previous whelping was a difficult par vaginal delivery and the owner requested that the patient be spayed. Vaccination and deworming history were adequate.

## PHYSICAL AND CLINICAL EXAMINATION

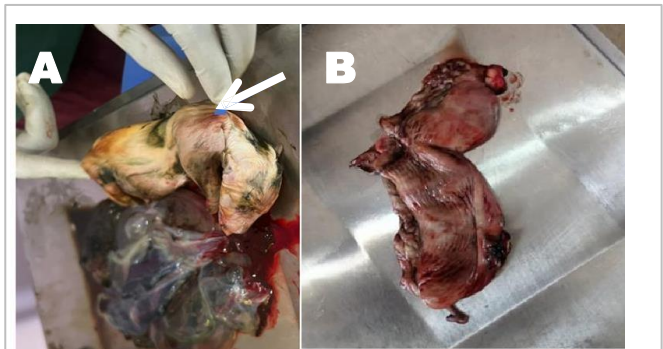
The vital physiologic parameters that include temperature (37.9 °C), pulse rate (124 beats/min) and respiratory rate (30 cycles/min) were normal and within the normal reference range of Hassan and Hassan (2003).

The bitch was restless and straining (abdominal contractions). The ocular and mucous membranes were pinkish (normal). Moving foetal-like masses cranial to the ventral pelvic region was palpated abdominally. An ultrasound machine was not available to confirm the viability of foetal masses. The cervix was slightly dilated and Ferguson's reflex was present. There was a protruding membrane from the vagina and foetal body structures could be digitally palpated per vagina. Poking the foetal structures did not induce any reflex response. There was no room for manipulation. Dystocia was tentatively diagnosed, and an emergency caesarian sectioning (CS) and ovariectomy (OVH) were indicated. The client signed a consent form for CS and OVH.

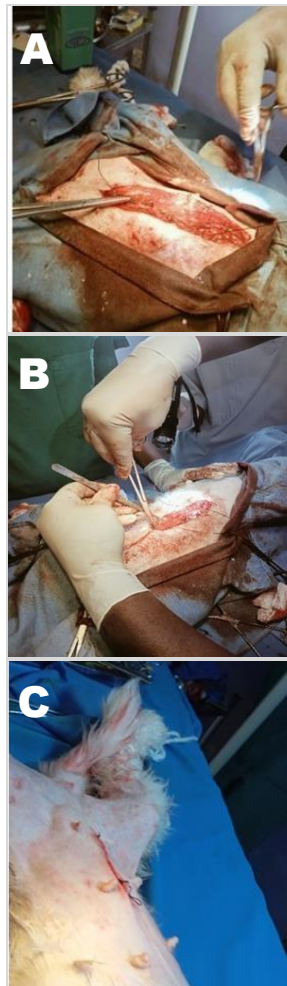
## CAESARIAN SECTIONING AND OVARIOHYSTERECTOMY

The prognosis was good. The patient was placed on lateral recumbency, and the ventral abdominal and pelvic regions were shaved, washed and scrubbed using chlorhexidine gluconate and gauze, and cleaned with methylated spirit. An anaesthetic protocol consisting of atropine at 0.02 mg/kg IM, xylazine at 1.0 mg/kg IV and ketamine at 5.0 mg/kg IM was instituted. Standard laparotomy, hysterotomy, foetal extraction, and OVH were performed as described by Romagnoli *et al.* (2024). One dead foetus and two life foetuses in normal longitudinal presentation and dorso-sacral position were retrieved with their placentae and handed over to an assistant. The dead foetus (Fig. IA) was located at the cervix and had a right shoulder flexion and right lateral deviation of the head. The ovary-uterine organ was excised (Fig. IB) and the incision wound was lavaged with sterile warm saline containing penicillin-streptomycin. The peritoneum and muscles were sutured using polyglactin (Vicryl®) size 2-0 in a simple continuous suture pattern. The sub-cutaneous tissue was sutured in a subcuticular running

pattern using polyglactin. The suture site was dressed with an antimicrobial wound spray (Nutri-Vet® - 0.13% Benzalkonium Chloride in aloe vera per spray).



**Figure I: Obstetrical findings at cesarean sectioning and ovariectomy.** (A) The dead foetus showing white arrow pointing to erythema on a swollen flexed right shoulder of the foetus. (B) Ovariectomized tissue.



**Figure II: Wound closure of incision site** (A) Suture of the peritoneum and muscles in a simple continuous pattern. (B) Subcuticular pattern suture of subcutaneous tissue. (C) Completed wound closure.

**POST-OPERATIVE MANAGEMENT**

Blood was collected from the cephalic vein for haematology and the bitch was admitted for three days. Anti-inflammatory, antibiotics, haematinics and vitamins constituted the postoperative treatment, viz: meloxicam 0.2 mg/kg IM x2/7 (Metacam®; Boehringer Ingelheim Animal Health USA Inc.), ceftriaxone 15 mg/kg IM x 3/7 (Rocephin®; F. Hoffmann-La Roche Ltd, Switzerland), vitamin B. complex 0.1 ml/kg IM x 2/7 (Ryan Pharma®; Shanghai Ryan Pharma Co., Ltd., China), vitamin C 1.5 ml IM x 1/7 (VitCCare 25% AdvaCare Pharma, USA) and daily wound dressing with 0.13% Benzalkonium Chloride in aloe vera per spray. An improvised Elizabethan collar was placed around the patient's neck. The haemogram showed anaemia, lymphocytic leucocytosis, neutropenia and thrombocytopenia (Table I). The patient's normal vital physiologic parameters during the three days of post-surgery observation were normal (Table II).

**NEONATAL CARE**

The clinic assistant collected the life foetuses with their placentae and quickly removed the foetal membranes with a soft gauze. Excess fluid was extracted from the nostrils and mouth with a Pasteur pipette. The attachment of the umbilical cords to the placentae was clamped to contain bleeding and severed. The two life foetuses were then wrapped in warm towels and rubbed several times until they made audible sounds. The puppies were transferred to a carton with a warmed dry towel at the base. The puppies were guided to suckle from their dam immediately after she recovered from anaesthesia.

The patient and her neonates were discharged on the third day after surgery as the dam's appetite was good. The wound site healed progressively throughout the three days of observation, and the puppies were in good body condition and suckled normally.

**DISCUSSION**

The current case report highlights the importance of monitoring the timing of events during canine pregnancy and parturition and the potential risks of delays in intervention. The clear fluid vaginal discharge observed by the client more than two hrs before the patient was presented to the clinic was the amniotic fluid sequel to the rupture of the foetal sac and evidenced by the whitish membrane protruding through the vagina.

The current case of dystocia also emphasises the importance of properly examining dystocia patients before decisions are made on the type of management to institute. A further delay by manipulating to achieve vaginal delivery or retraction could have led to the deaths of the foetuses that were still

viable at the time of presentation. The history of duration of events, the presence of more than one foetus and insufficient room for manipulation were enough reasons for emergency

**Table I: Post-surgery haemogram**

Blood parameters	Test Value	*Reference	Remark
Hb (G/gl)	8.5	11.9 -18.9	Low
PCV (%)	26	35 - 57	Low
RBC (x10 <sup>12</sup> /l)	3.2	4.95 -7.87	Low
MCV (fl)	73	66 -77	Normal
MCH (pg)	26	21.0 - 26.2	Normal
MCHC (g/dl)	37	32.0 - 36.3	High
WBC (x10 <sup>9</sup> /l)	14.3	5.0 - 14.1	High
Platelets (x10 <sup>9</sup> /l)	174	211 - 621	Low
Neutrophils (%)	46	58 - 85	Low
Lymphocytes (%)	45	8 - 21	High
Monocytes (%)	7	2 - 10	Normal
Eosinophils (%)	2	0 - 9	Normal
Basophils (%)	--	0 - 1	Normal

\* (Fielder, 2022)

Interpretation: Normocytic Normochromic Anaemia, Neutropenia and Lymphocytic leucocytosis, Thrombocytopenia

**Table II: Vital physiologic parameters post-surgery**

Day post-surgery	Temperature (°C)	Pulse Rate (Beats/ min)	Respiratory Rate (Cycles/min)	Remark
Day-1	38.3	112	22	Normal
Day-2	38.4	116	23	Normal
Day-3	38.4	118	22	Normal
*Reference range	37.8 – 39.2	110 - 130	20 -30	

\*Hassan and Hassan (2003)

surgery to deliver the live foetuses. Schrank *et al.* (2022) reported that fewer stillbirths were recorded when an emergency C-section was performed before the first puppy was born than after one puppy was delivered.

The current case suggested an ongoing stage II delivery that has been halted for about 2 hrs. Perhaps the first foetus in transit to delivery ruptured its foetal sac as its right shoulder collided with the dam's pelvic brim and got trapped causing difficulty in parturition. The cause of the foetal death could have been due to trauma as erythema was observed on a swollen right shoulder.

The patient's haematology profile of anaemia and lymphocytosis was not considered part of a disease process within the circumstance of dystocia. Kakkassery *et al.* (2023)

asserted that transient anaemia may occur peripartum in dystocia cases but resolves 72 hrs postpartum. Lymphocytosis is suggestive of the active immune response related to corpus luteum lysis and characteristic of the termination of pregnancy in canines (Kakkassery *et al.*, 2023). Thrombocytopaenia may be due to the non-steroid anti-inflammatory drug, meloxicam. Ranieri (2013) associated thrombocytopenia with meloxicam administration in a human patient. Meloxicam may also be responsible for the neutropenia observed in the current case as it causes neutropenia in mice (Ghulam *et al.*, 2023). The haemogram was post-operative after meloxicam was administered. Another haemogram about four days later was required to rule out a disease process. However, the vital physiologic parameters were consistently normal during the three days of observation and the reports from the owner over two weeks suggested that the patient was healthy. Absorbable suture material was used for the wound suture and there was no need for the client to return with the patient for the suture removal after the wound had healed.

## REFERENCES

- Fielder, S.E. (2022). Haematologic reference ranges. Retrieved from <http://www.msdivetmanual.com/special-subjects/reference-guides/Haematologic-referencerranges>
- Ghulam. F., Javeed, A., Ashraf, M., Syed, S.K., Zahoor, B. (2023). Evaluation of the immunomodulatory activity of meloxicam in vitro and in vivo. *Tropical Journal of Pharmaceutical Research*, 22(6), 1231-1236.
- Hassan, A.Z. & Hassan, F.B. (2003). *Basic clinical services. An introduction to veterinary practice*. Zaria-Nigeria, Ahmadu Bello University Press Limited.
- Kakkassery, M.P., Choppillil, J., Thomas, N., Abhilash, R.S., Harshan, H.M., Ajithkumar, S. (2023). Haematology profile of dogs with primary uterine inertia. *Journal of Veterinary and Animal Sciences*, 54(1), 7 – 12.
- Pasch, A. (2024). The prevalence of dystocia in Purebred dogs; Part 2: research paper. A dissertation submitted to Ghent University in partial fulfilment of the requirements for the degree of Master of Veterinary Medicine Academic year: 2023 – 2024. Retrieved (9 November 2024) from: [https://libstore.ugent.be/fulltxt/RUG01/003/145/322/RUG01-003145322\\_2023\\_0001\\_AC.pdf](https://libstore.ugent.be/fulltxt/RUG01/003/145/322/RUG01-003145322_2023_0001_AC.pdf)
- Ranieri, M.M., Bradley, E.F., Simon, A.B. (2013). Meloxicam-induced thrombocytopenia. *Pharmacotherapy*, 34(2), e14 -17.
- Romagnoli, S., Krekeler, N., de Cramer, K., Kutzler, M., McCarthy, R., Schaefer-Somi, S. (2024). Surgical sterilization in dogs and cats. In: WSAVA guidelines for the control of reproduction in dogs and cats. *Journal of Small Animal Practice*, 65(7), 424 – 457.
- Schrank, M., Contiero, B., & Mollo, A. (2022). Incidence and concomitant factors of cesarean sections in the bitch: A questionnaire study. *Frontiers in Veterinary Science*, 9, 934273.