

## Case report of colibacillosis in a 33-week-old layer flock

<sup>1</sup>\*Sanda M.E., <sup>1</sup>Ngene A.C., <sup>1</sup>Okwara N.K. <sup>2</sup>Aronu C. J. & <sup>1</sup>Tchokote E.Y.

<sup>1</sup>Department of Veterinary Medicine, College of Veterinary Medicine, Michael Okpara University of Agriculture, Umudike,

<sup>2</sup>Faculty of Veterinary Medicine, University of Nigeria, Nsukka

\*Correspondence: okwara.nneoma@mouau.edu.ng, +234 8067994835

### ABSTRACT

This case report is that of colibacillosis infection in a 33-week-old layer flock. The flock had 6,200 laying Isa brown pullets. The primary complaint was reduced feed intake, a drop in egg production (from 78% to 51%), whitish-green watery faeces, persistent mortality and poor quality of eggs. The birds were vaccinated 2 weeks before farm visit and were previously treated with Amoxycol<sup>(R)</sup> and liver tonic by the farmer. Physical examination revealed sneezing, nasal discharge, somnolence, perineum matted with whitish-green faeces and lethargy. Post mortem examination revealed pneumonic and edematous lungs, slightly enlarged friable liver with necrotic pallor, perihepatitis and mucoid enteritis. Culture of the samples collected showed that the isolate was *Escherichia coli* while the Antimicrobial Sensitivity Test results from collected blood and liver samples showed that the isolate was sensitive to Gentamycin, Enrofloxacin, and Doxygen<sup>(R)</sup> but resistant to Furaltone, Tylosin tartrate and Amoxycol<sup>(R)</sup>. The flock was placed on Doxygen<sup>(R)</sup> at 100g per 400 liters of drinking water for 5 consecutive days. The farmer was advised to maintain strict biosecurity measures within the farm premises and to include Isochlor<sup>(R)</sup> in the drinking water of the flock.

**Keywords:** *Escherichia coli*, Colibacillosis, Isa brown, Layers

### INTRODUCTION

Colibacillosis, a syndrome caused by *Escherichia coli* (*E. coli*), is one of the most common infectious bacterial diseases of the layer industry. *Escherichia coli* is always found in the gastrointestinal tract of birds and disseminated widely in faeces; therefore, birds are continuously exposed through contaminated faeces, water, dust and the environment (Charlton, 2006). Birds of all ages are found to be susceptible to colibacillosis (Johnson *et al.*, 2001). Factors affecting host susceptibility for colibacillosis include compromised skin or mucosal barriers (for example, unhealed navel, wounds, mucosal damage from infections), immunosuppression, nutritional deficiencies, environmental contaminants, poor ventilation, contaminated water and stress exposure (Barnes *et al.*, 2013). Multiple antimicrobial resistance traits of avian pathogenic *E. coli* have been associated with transmissible R-plasmids (Timothy *et al.*, 2005).

### CASE HISTORY AND PHYSICAL EXAMINATION

History revealed that 33-week-old Isa brown layers with a flock size of 6,200 and average body weight of 1.6kg started dying (mortality rate of 4%) five days prior to farm visit. The birds were housed in battery cages, fed on commercial feed.

Feed and clean water were provided for the birds *ad libitum*. The flock was vaccinated which vaccine and route of administration about 2 weeks before the visit. They were also previously treated with Amoxycol<sup>(R)</sup> (Amoxicillin, Colistin) and liver tonic by the farmer.

The primary complaints include reduced feed intake, a drop in egg production (from 78% to 51%), watery greenish white faeces, poor quality of eggs, persistent mortality and lethargy. Physical examination revealed respiratory signs such as sneezing and nasal discharge. Somnolence, perineum matted with greenish white faeces and lethargy were also observed.

### POST MORTEM EXAMINATION

The following lesions were observed when post mortem examination was carried out: slightly enlarged friable liver with necrotic pallor (Fig I), pneumonic and oedematous lungs (Fig II), mucoid enteritis (Fig III) and perihepatitis.

**DIFFERENTIAL DIAGNOSES:**

Among the differential diagnoses of the condition are Colibacillosis, Fowl Typhoid and Chronic Respiratory Disease

**TENTATIVE DIAGNOSIS:** Colibacillosis was chosen as tentative diagnosis based on the predominant clinical symptoms and pathological lesions.

**LABORATORY RESULTS:**

A carcass and 2mls of blood sample from one of the birds were taken to laboratory for culture on nutrient agar and Eosin Methylene Blue (EMB) using standard procedures. Antimicrobial sensitivity test was also conducted using the disc diffusion procedure (Bauer, 1998). The antimicrobials tested were (eg Gentamycin 10 mcg, Enrofloxacin 10 mcg etc). The isolates were classified as sensitive, intermediate or resistant to each of the antibiotics according to the Clinical and Laboratory Standard Institute (CLSI), (2012).

**Table I: Antimicrobial Sensitivity Test result from collected blood and liver samples**

SENSITIVE	INTERMEDIATE	RESISTANT
Gentamycin	Streptomycin	Furaltadone
Enrofloxacin	Colistin	Tylosin tartrate
Doxycycline		Amoxicillin

**CONFIRMATORY DIAGNOSIS**

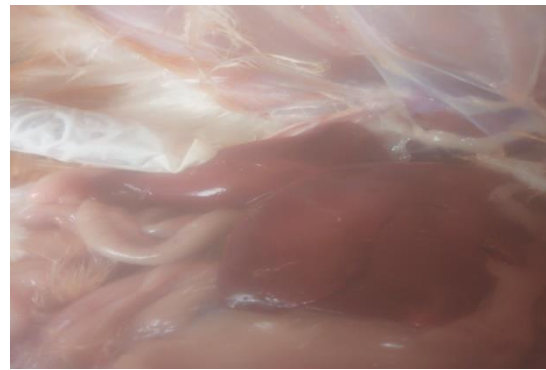Based on history, physical examination, observation of clinical signs, post mortem examination and laboratory analysis, the case was confirmed to be colibacillosis

**TREATMENT AND MANAGEMENT**

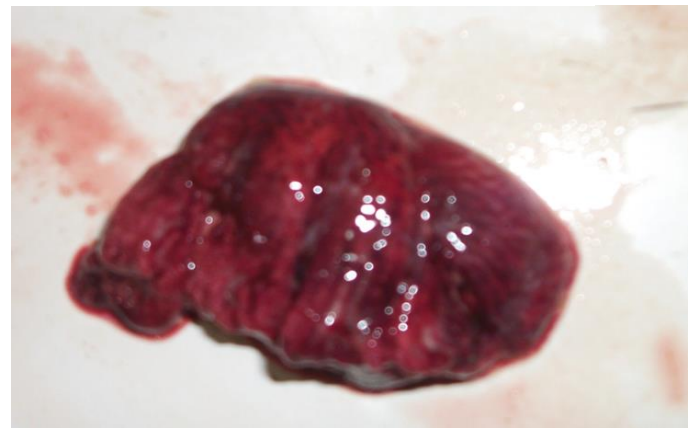
Doxygen® (Gentamycin, Doxycycline) was administered at 100g per 400 liters of drinking water for 5 consecutive days, Vitaminolyte<sup>(R)</sup> (Multivitamin, Amino-acids and Electrolytes) was given to the birds at 1g/2litres × 6/7, Anilivfit<sup>(R)</sup> (Sorbitol, L-Carnitine, Choline, Methionine, Lysin, Betaine) was also administered at 1ml/2 litres drinking water × 5/7.

**DISCUSSION**

Colibacillosis, a syndrome caused by *Escherichia coli* (*E. coli*), is one of the most common infectious bacterial diseases of the layer industry. It causes significant economic losses (due to high mortality rates) worldwide (Regione and Woodward, 2002; Vegad and Katiyar, 2008). Colibacillosis has been reported to cause sporadic deaths both in layer and breeder flocks and has been noted to be the most common layer cause of mortality in commercial layer and breeder chickens (Nolan *et al.*, 2013).



**Figure II: Pneumonic and oedematous lungs**

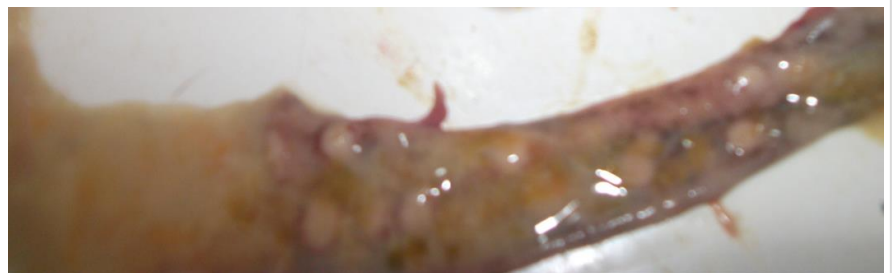

**Figure II: Pneumonic and oedematous lungs**

*Escherichia coli* is always found in the gastrointestinal tract of birds and

disseminated widely in faeces; therefore, birds are continuously exposed through contaminated faeces, water, dust and the environment (Charlton, 2006). Multiple antimicrobial resistance or Multidrug resistance (MDR) traits of avian pathogenic *E. coli* have been associated with transmissible R-plasmids (Timothy *et al.*, 2005).

Clinical signs observed in this present case such as drop in feed intake, watery greenish white faeces and persistent mortality is in agreement with those reported by Amit *et al.*



**Figure.III: Mucoïd enteritis**

(2019) where colibacillosis was reported in broilers. Post mortem lesions observed in this case such as perihepatitis

also agrees with same reported by Amit *et al.* (2019). The reduction in egg production and mortality observed is similar to that reported by Vandekerchove *et al.* (2003) as seen in colibacillosis in caged layer hens.

The antibiotic treatment (Doxygen®) (Gentamycin, Doxycycline) was administered for the treatment of the bacterial infection in the birds although broad spectrum antibiotics such as sulfa drugs and gentamycin are commonly used to control the infection (Singh *et al.*, 2011).

Anilivfit<sup>(R)</sup> was administered to help the activities of the liver, because of decrease in weight and bone breaking strength due to possible increase in the amount of endotoxin in blood circulation (Mireles *et al.*, 2005).

Vitaminolyte<sup>(R)</sup> which contains; Vitamins A, C, D, E along with selenium,  $\beta$ -carotene and iron, was given to improve the bird's immune status (Shane, 2001; Sanda *et al.*, 2015).

Cessation of mortalities after onset of therapy indicates that Doxygen® (which was chosen as the drug of choice based on sensitivity test) was effective.

## CONCLUSION

From the findings of this present study, it is noted that administration of Doxygen (through drinking water) for 5 days together with vitamins and Anilivfit® was effective for the treatment of colibacillosis in layers.

## ADVICE TO THE CLIENT

The farmer was advised to maintain strict biosecurity within the farm premises and to include 5gm Isochlor® (water sanitizer containing Sodium dichloro isocyanurate 55%) to 1,000 liters of drinking water for the flock. Also, adherence to strict general hygiene in the poultry farm to control the disease was advised.

## REFERENCES

- Amit Baranwal, N.P. Singh, Ashok Kumar, Avneesh Kumar, P.K. Upadhyaya and A.K. Srivastava. Colibacillosis in Broilers: A case report (2019). *Journal of Entomology and Zoology Studies*. 2019; 7(5): 163-166.
- Barnes H.J., Nolan L.K., Vaillanwurt J.P. Colibacillosis, *Diseases of Poultry*. 13<sup>th</sup> ed. Ch. Ames:Wiley-Blackwell, Print, 2013, 716-757.
- Baur A.W., Kirby W.M., Sherris J.C. and Turck M. (1996). Antibiotic susceptibility testing by a standardized single disk method. *American Journal of Clinical Pathology*, 45: 493-496.
- Charlton, B.R. 2006. *Avian Disease Manual*. 6<sup>th</sup> edn. American Association of Avian Pathologists. Athens.
- CLSI (2012). Performance standards for antimicrobial susceptibility testing. *Clinical and Laboratory Standard Institute (CLSI)*. Twenty Second Informational Supplement M100-S22, 32 (3): 10-78.
- Johnson L.C., Bilgili S.F., Hoerr F.J., Murtrey B.L., Norton R.A. The influence of *Escherichia coli* strains from different sources and the age of broiler chickens on the development of cellulitis. *Avian Pathol*. 2001; 30: 475-479.
- Mireles A.J., Kim S.M., and Klassing K.C. 2005. An acute inflammatory response alters bone homeostasis, body composition, and the humoral response of broiler chickens. *Poultry Science*, 84: 553-560.
- Nolan L. Colibacillosis. *Diseases of Poultry*. 13<sup>th</sup> Edition. Ames: Wiley-Blackwell, 2013. Chapter 18.
- Regione R.M., Woodward M.J. Virulence factors of *Escherichia coli* serotypes associated with avian coli septicemia. *Res. Vet. Sci*. 2002; 73:27-35.
- Sanda M.E., Ezeibe M.C.O. and Anene B.M. 2015. Effects of Vitamins A, C and E and Selenium on immune Response of Broilers to Newcastle (ND) Vaccine. *IOSR Journal of Agriculture and Veterinary Science* 8(7), 13-15.
- Shane, S.M. 2001. Coliform infections are responsible for heavy losses. *World Poultry*, 17(9): 58-59.
- Singh S.D., Tiwari, R. and Dhama, K. 2011. Avian colibacillosis, an economically important disease of young chicks. *Poultry World*, October issue. Pp: 14-20.
- Timothy J. Johnson, Kylie E. Siek, Sara J. Johnson and Lisa K. Nolan, 2005. DNA sequence and comparative genomics of pAPEC-O2-R, an avian pathogenic *Escherichia coli* transmissible R Plasmid. *Antimicrobial agents and chemotherapy*, Nov. 2005, p.4681-4688. American Society for Microbiology.
- Vegad J.D, Katiyar A.K. 2008. A textbook of Veterinary Special Pathology (Infectious Diseases of Livestock and Poultry), 3<sup>rd</sup> Reprint. Ch.3. IBDC Print, 2008, 293-295.
- Vandekerchove D., De Herdt P., Laevens H., and Pasmans F. 2004. Colibacillosis in caged layer hens: characteristics of the disease and the aetiological agent. *Avian Pathology*. Vol: 33,2004, issue 2.