

CLINICO-PATHOLOGY OF EXPERIMENTALLY INFECTED COCCIDIOSIS IN BROILER CHICKENS

^{1&4}UKONU, C.E., ²AKPAN, A.J., ¹NWABUEZE I.N. & ³OGO, I. N.

¹Farming System Research Programme, National Root Crops Research Institute, Umudike, Nigeria. ²Michael Okpara University of Agriculture, Umudike. ³National Veterinary Research Institute, Vom, Nigeria. ⁴Root for Health Unit, National Root Crops Research Institute, Umudike, Nigeria

*Correspondence: erastusdavid4real@gmail.com

ABSTRACT

Coccidiosis remains the most economically significant parasitic disease in poultry production, impacting bird health and farm profitability. This study investigated the clinical signs and pathological effects of coccidiosis in broiler chickens, and the response to treatment. Forty-five day-old broiler chicks were randomly assigned into three groups (A–C), each with 15 birds: Group A (uninfected, untreated control), Group B (infected, untreated), and Group C (infected, treated with amprolium 1g/2L). Gross lesions in infected birds (Groups B and C) included distended caeca with clotted blood, caseous debris, petechiation, mucosal thickening, and ecchymosis. Clinical and pathological recovery was observed from day 14 post-infection, particularly in the treated group. Histologically, Group B exhibited severe mucosal erosion, ulceration, and abundant oocysts and schizonts, accompanied by oedema, haemorrhages, and cellular infiltration. The liver showed sinusoidal congestion, hypoplastic lymphoid aggregates, and focal hepatocyte degeneration. Group C displayed similar but milder lesions. Activity and fecal scores declined significantly in infected birds, correlating with increased oocyst counts. The worsening pathology impaired intestinal mucosa, reducing nutrient absorption and feed conversion efficiency. The findings underscore the detrimental impact of coccidiosis on broiler health and performance. Treated birds (Group C) showed improved clinical outcomes, highlighting the importance of timely therapeutic intervention. The study recommends preventive management strategies and prophylactic treatment to mitigate economic losses associated with coccidiosis. Ultimately, maintaining gut integrity is essential for optimal productivity in broiler operations.

Keywords: Clinico-pathology, coccidiosis, petechiation, cellular infiltration

INTRODUCTION

Poultry production, especially broiler chicken farming, is among the fastest-growing sectors in global agriculture. This expansion is driven by the increasing demand for affordable animal protein and the short production cycle of broilers, making them economically viable for both large-scale operations and smallholder farms. Broiler chickens are bred for rapid weight gain and efficient feed conversion, making them ideal for meat production. In many low- and middle-income countries, poultry farming supports household food security, income generation, and employment throughout the value chain. However, infectious diseases pose a serious threat to productivity and profitability (Abdu & Musa, 2014;

Okonkwo *et al.*, 2019; Ukonu, *et al.*, 2023). A major disease of economic concern is coccidiosis, caused by protozoa of the genus *Eimeria*. These intracellular parasites infect epithelial cells of the intestinal lining, causing intestinal damage that varies by species. Coccidiosis spreads rapidly under poor sanitation, high stocking density, and warm, humid conditions common in intensive systems. The clinical presentation of coccidiosis in infected birds include watery or bloody diarrhoea, anorexia, dehydration, ruffled feathers, huddling, and poor growth. Severe cases, particularly in young or immunocompromised birds, can lead to high mortality (Okonkwo *et al.*, 2019; Ukonu, *et al.*, 2023). Pathologically, coccidiosis presents with gross and microscopic lesions. For

example, *E. tenella* causes haemorrhages and caseous cores in the caeca, while *E. acervulina* leads to whitish striations in the duodenum. *Eimeria maxima* and *E. necatrix* result in intestinal ballooning and necrosis. Histological findings include villus atrophy, epithelial desquamation, necrosis, mononuclear infiltration, and the presence of various parasite stages, all of which impair nutrient absorption and may lead to secondary bacterial infections (Degoussein, 2007). These intestinal damages reduce feed efficiency, slow growth, and increase susceptibility to other infections like *Clostridium perfringens*. Infection stress may also lower vaccine response and cause chronic health issues. Economically, this results in higher mortality, treatment costs, reduced carcass weight, and product downgrading (Conway & McKenzie, 2007). Globally, coccidiosis causes over \$3 billion in losses annually through direct impacts (mortality, poor growth) and indirect costs (control and prevention) (Blake *et al.*, 2020). Williams (1999) estimated the disease accounts for more than 20% of all poultry disease-related economic losses (Morris & Gasser, 2006). With rising drug resistance, focus has shifted to prevention—vaccination, anticoccidial feed additives, biosecurity, and litter management prove more effective than late-stage treatment (Wakenell, 2010). This study explores the clinical signs and pathology of coccidiosis, emphasizing early detection and prevention to improve broiler productivity, health, and economic returns.

MATERIALS AND METHODS

STUDY LOCATION AND PERIOD

The study was carried out at the Michael Okpara University of Agriculture, Umudike (MOUAU) in the Department of Veterinary Pathology, College of Veterinary Medicine. MOUAU is located between 5°28'33"N and 7°32'56"E (Anonymous, 2014). The study was conducted between December 2019 and April 2020 for the *Eimeria* experimental infection.

EXPERIMENTAL DRUG

Amprolium (Amprolium 250WSP®) is a commercially available anticoccidial drug for the routine treatment of avian coccidiosis (due to *Eimeria* species).

EIMERIA SPECIES STRAINS

The sporulated oocysts used to infect the animals were obtained from the Parasitology Department of the National Veterinary Research Institute, Vom, Jos, Plateau State. The collected field strains of sporulated *Eimeria tenella* oocysts were packaged and preserved in an ice pack and transported to the Department of Pathology, College of Veterinary Medicine, Michael Okpara University of Agriculture, Umudike, Abia State. On arrival, the sample was confirmed to contain sporulated *Eimeria* oocysts with a light microscope

and then stored in the refrigerator at 4°C and was used within two weeks for the studies.

STUDY POPULATION

Forty-five (45) day-old Ross 308 broiler unsexed chicks, obtained from a local commercial broiler hatchery, were used for the experiment. The birds were kept under good hygienic conditions. Drinking water and feed were offered *ad libitum*. Chicks were fed on a balanced commercial ration free from anticoccidials. The chicks were floor-reared in separate units throughout the experimental period. They were routinely vaccinated against Newcastle and infectious bursal diseases.

EXPERIMENTAL DESIGN

A total of forty-five day-old Ross 308 broiler chicks were divided randomly into three equal groups (from Groups A to C) and weighed by a restricted randomized procedure (RRP) that initially equalised their weights. Each group comprised 15 chicks with three replicates in each group, and each replicate had five chicks. The groups were arranged as follows:

Group A: Control (uninfected - untreated).

Group B: Infected - untreated.

Group C: Infected - treated (with Amprolium 1g/2L of water).

Birds in groups B and C were infected with an equal dose of 10,000 sporulated *Eimeria tenella* oocysts per bird per os at the 14th day of life. Treatment by drug was started in the drinking water according to the recommendation by the manufacturer at the 6th day post infection (20th day of age) or following the appearance of oocysts in faecal samples (oocysts were detected in the faeces of chickens by day 5 PI, and the treatment started the next day, the 6th day PI).

Clinical examination

The clinical signs, such as depression, were checked by activity score, and diarrhoea was checked by faecal score and recorded. The severity of diarrhoea (faecal score); a scale of 1–5 was used to measure normal faeces and the degree of deviation from normal as follows: 5 – no diarrhoea, 4 – mild, 3 – moderate, 2 – marked, and 1 – more marked diarrhoea. A similar scale was used for the activity score. (Okonkwo *et al.*, 2019; Ukonu, *et al.*, 2023).

OOCYST COUNTS

Fresh faecal droppings were collected randomly from the litter spread on the ground from each group for daily oocyst counts from the 4th till the 19th day post infection (PI) until when only few or no oocysts could be detected in faecal droppings (related to the oocyst shedding curve of the control group). The mean number of oocysts per gram of faeces for each group was counted, and for the large counts, the McMaster counting technique according to the method described by Long *et al.* (1976) was used.

NECROPSY EXAMINATION AND HISTOPATHOLOGY

Necropsy was done on all birds that died during the experiment. Also from day 10 PI, 3 birds per group were euthanized at varied intervals till the end of the experiment for necropsy and histopathology. Gross lesions were determined by macroscopic examination of the intestine and caeca of each bird using Elbahy *et al.* (2006) as a guide. Sections of the caeca and liver were collected in 10.0% buffered neutral formalin and processed for histopathological examination at the Department of Veterinary Pathology Laboratory of Michael Okpara University of Agriculture, Umudike.

STATISTICAL ANALYSIS

The data obtained from this study were presented as means \pm SEM (standard error of means) and were statistically analysed using analysis of variance (Two-way ANOVA). Comparison of groups was performed using the least significant difference (LSD) at $P < 0.05$ according to Petrie and Watson (1999). Other results were presented in Figures.

RESULTS

THE ACTIVITY SCORE OF BROILER CHICKENS EXPERIMENTALLY INFECTED WITH SPORULATED *EIMERIA TENELLA* OOCYSTS

The activity scores of broiler chickens are presented in Table I. By day 0 PI, the activity of birds across the groups were similar. By day 4 PI, the two infected groups became significantly less active than the control. Reduced activities were more severe from day 4 PI to day 11 PI in the infected groups but was generally more marked with group B than group C. Thereafter from day 12 PI, activity scores improved in the two infected groups, particularly in group C in which activity returned to normal by 17 PI.

FAECAL SCORES OF BROILER CHICKENS EXPERIMENTALLY INFECTED WITH SPORULATED *EIMERIA TENELLA* OOCYSTS

The activity scores of broiler chickens are presented in Table I. By day 0 PI, the activity of birds

The faecal scores of broiler chickens are presented in Table II. By day 0 PI, the faecal score across the groups were similar. By day 4 PI, the faecal scores of groups B and C became significantly low than the control group. The faecal scores of the infected groups were markedly low from day 4 PI to day 11 PI but it was generally more marked with group B than group C. Their faecal scores improved from day 12 PI, in the two infected groups, particularly in the infected treated group in which faecal score returned to normal by day 15 PI.

Table I: Activity scores of broiler chickens experimentally infected with sporulated *Eimeria tenella* oocysts

Days PI	Groups		
	A	B	C
0	5.0 \pm 0.0*	5.0 \pm 0.0	5.0 \pm 0.0
4	5.0 \pm 0.0 ^a	3.7 \pm 0.3 ^b	3.7 \pm 0.3 ^{cb}
5	5.0 \pm 0.0 ^a	2.7 \pm 0.3 ^b	2.3 \pm 0.3 ^{cb}
6	5.0 \pm 0.0 ^a	1.0 \pm 0.0 ^b	1.0 \pm 0.0 ^{cb}
7	5.0 \pm 0.0 ^a	1.0 \pm 0.0 ^b	2.0 \pm 0.0 ^c
8	5.0 \pm 0.0 ^a	1.3 \pm 0.3 ^b	1.3 \pm 0.3 ^{cb}
9	5.0 \pm 0.0 ^a	1.6 \pm 0.0 ^b	1.7 \pm 0.3 ^{cb}
10	5.0 \pm 0.0 ^a	2.0 \pm 0.0 ^b	3.0 \pm 0.0 ^c
11	5.0 \pm 0.0 ^a	2.7 \pm 0.3 ^b	3.3 \pm 0.3 ^{cb}
12	5.0 \pm 0.0 ^a	3.0 \pm 0.0 ^b	3.7 \pm 0.3 ^c
13	5.0 \pm 0.0 ^a	3.0 \pm 0.0 ^b	4.0 \pm 0.0 ^c
14	5.0 \pm 0.0 ^a	4.0 \pm 0.0 ^b	4.0 \pm 0.0 ^{ab}
15	5.0 \pm 0.0 ^a	4.0 \pm 0.0 ^b	4.3 \pm 0.3 ^{cb}
16	5.0 \pm 0.0 ^a	4.0 \pm 0.0 ^b	4.7 \pm 0.3 ^{ac}
17	5.0 \pm 0.0 ^{NS}	4.3 \pm 0.3 ^{NS}	5.0 \pm 0.0 ^{NS}

*Different superscript letters indicate significant differences ($p < 0.05$) in rows. Superscript NS= not significant. Day= day of live. *= mean \pm SEM.*

Table II: Faecal scores of broiler chickens experimentally infected with sporulated *Eimeria tenella* oocysts

Days PI	Groups		
	A	B	C
0	5.0 \pm 0.0*	5.0 \pm 0.0	5.0 \pm 0.0
4	5.0 \pm 0.0 ^a	1.7 \pm 0.3 ^b	1.3 \pm 0.3 ^c
5	5.0 \pm 0.0 ^a	1.0 \pm 0.0 ^b	1.0 \pm 0.0 ^{cb}
6	5.0 \pm 0.0 ^a	1.0 \pm 0.0 ^b	3.0 \pm 0.0 ^{cb}
7	5.0 \pm 0.0 ^a	1.7 \pm 0.0 ^b	2.0 \pm 0.0 ^{cb}
8	5.0 \pm 0.0 ^a	1.0 \pm 0.0 ^b	3.3 \pm 0.3 ^c
9	5.0 \pm 0.0 ^a	2.0 \pm 0.0 ^b	2.0 \pm 0.3 ^{cb}
10	5.0 \pm 0.0 ^a	3.0 \pm 0.0 ^b	3.3 \pm 0.0 ^{cb}
11	5.0 \pm 0.0 ^a	3.0 \pm 0.0 ^b	3.0 \pm 0.0 ^{cb}
12	5.0 \pm 0.0 ^a	4.0 \pm 0.0 ^b	4.0 \pm 0.3 ^{cb}
13	5.0 \pm 0.0 ^a	4.0 \pm 0.0 ^b	4.0 \pm 0.0 ^{cb}
14	5.0 \pm 0.0 ^a	4.0 \pm 0.0 ^b	5.0 \pm 0.0 ^{ab}
15	5.0 \pm 0.0	5.0 \pm 0.0	5.0 \pm 0.0
16	5.0 \pm 0.0	5.0 \pm 0.0	5.0 \pm 0.0
17	5.0 \pm 0.0	5.0 \pm 0.0	5.0 \pm 0.0

*Different superscript letters indicate significant differences ($p < 0.05$) in the same row. *= mean \pm SEM. 1=very pronounced brown faeces, 2= pronounced brown faeces, 3 = brown faeces, 4 = slightly brown faeces and 5 =absence of brown faeces*

EXPERIMENTAL OOCYST COUNT OF BROILER CHICKENS EXPERIMENTALLY INFECTED WITH SPORULATED *EIMERIA TENELLA* OOCYSTS

The mean oocyst counts of experimental broiler chickens are presented in Table III. At days 0-4 PI, there was no detectable oocyst in the faecal samples of the three groups. The control had no oocysts throughout the period of the experiment. Group B showed oocysts in their faeces by day 5 PI

(384.0±5.0/Opg), and the oocysts increased with time, reaching the highest level of 2869.3±202.6/Opg by day 18 PI. However, oocyst counts dropped to 1696.3±207.4 by day 19 PI. Oocyst counts were similar in groups B and C birds, although they were slightly higher in group C birds. Following treatment with amprolium on day 7 PI, oocyst counts in group C declined to 1453.3±50.0/Opg on day 13 and to 618.0±463.5/Opg on day 19 PI.

CLINICAL SIGNS AND PATHOLOGY OF BROILER CHICKENS EXPERIMENTALLY INFECTED WITH SPORULATED *EIMERIA TENELLA* OOCYSTS

The clinical signs in groups B and C included depression, ruffled feathers, weakness, inappetence, haemorrhagic diarrhoea (Figure I) and reduced physical activity found in

each of the three replicates of groups B and C. The clinical signs persisted longer in group B while improvement was recorded in the group C from the time of treatment. The control group maintained normal activity and the caeca at necropsy did not show any visible deviation from the normal caecal structure histologically (Figure III and IV) unlike the infected groups (Figures V, VI & VIII). Grossly the lesion found in the groups B and C were ballooned caeca, with pouches distended with various quantities of clotted/unclotted blood, and caseous necrotic debris of caecal mucosa in the lumen within the first six days of infection (Figure I - II). These were visible from the serosal surface of the caeca as dark petechiation as well as, thickening and ecchymosis of caecal mucosae on cut surfaces. Groups B and C showed progressive recovery in lesion and clinically from day 14 PI

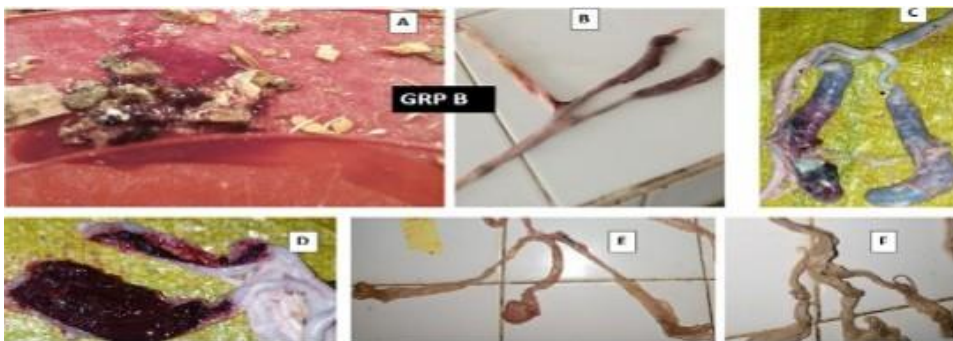

Figure I: Postmortem findings in broiler chickens infected with sporulated *Eimeria tenella* oocysts in group B. Note bloody faeces (A), ballooned and haemorrhagic caeca (B-D), bloody caecal core (D), and healing stage (E-F)



Figure II: Post mortem findings in broiler chicken in Group C birds. Note the caeca showed ballooning (b) and haemorrhagic core (h). Healing stages (C) at day 20 PI and D at day 42 PI.

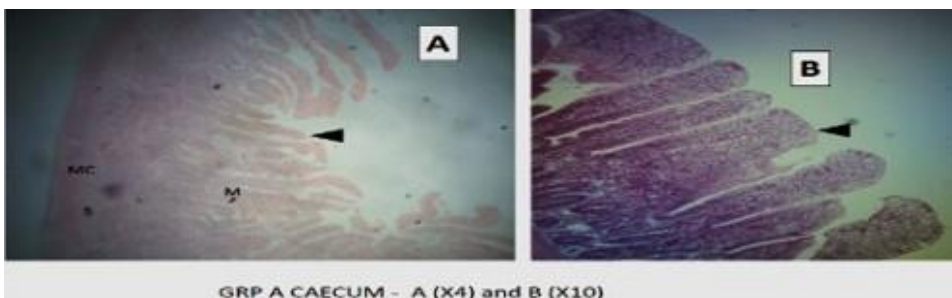


Figure III: Photomicrographs of caeca from broiler chickens in groups A and B showing intact epithelia (arrow head); MC= muscularis, S=submucosa and M=mucosa. H&E.

till the end of the experiment (Tables I– XII). Histopathology: Caeca in the control group appeared normal with the mucosa composed of closely arranged straight tubular glands, lined by enterocytes and goblet cells (Figure III and IV). In group B, the lining epithelium of the caecal mucosa showed areas of erosions and few points of ulceration, and the presence of oocysts and schizonts (Figures V - VII). The caeca in group C showed areas of erosions and the presence of oocysts and schizonts (Figures VIII - IX). Oedema, cellular infiltration and haemorrhages (inflammatory processes) were present in the caecal tissues of groups B and C (Figures V – VII and IX). The control showed normal mucosal architecture. While groups B and C showed erosion of the epithelial lining and oedema by day 6 PI (Figures V – IX). Following treatment, in group C, the mucosal architecture showed recovery. There were haemorrhage, heterophilic infiltration of the lamina propria of the caeca. Additionally there were presence of developmental stages of *Eimeria* spp. in the mucosa of the intestine (Figure IX). There were also mononuclear cell (lymphocytes, plasma cells and macrophages) infiltrations in the caecal mucosa (Figure IX). The liver hepatocytes in the control birds were normal with multifocal aggregations of lymphocytes in the periportal area (Figures X - XII).

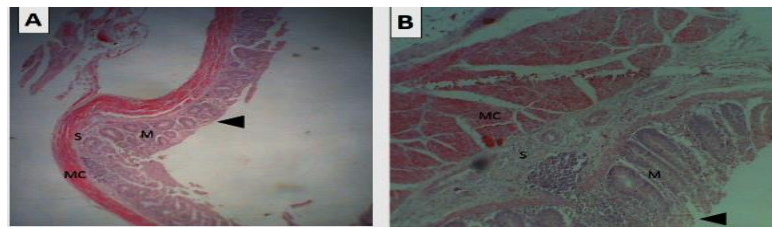


Figure IV: Photomicrographs of caeca from broiler chickens in group A (A and B) showing intact mucosa (arrow head); MC=muscularis, S=submucosa and M=mucosa. H&E Grp A Caeca X4 mag, B X10

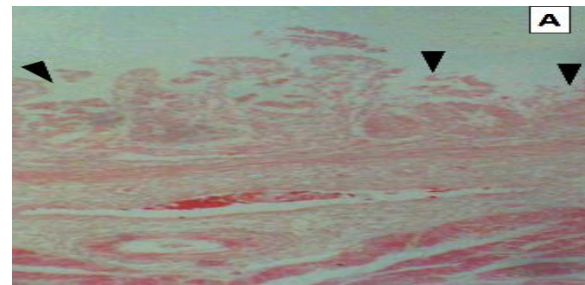


Figure V: Photomicrographs of caeca from broiler chickens infected with sporulated *Eimeria tenella* oocysts in group A showing ulceration and disorganization of the mucosa (arrow head).




Figure VI: photomicrograph of caeca from broiler chickens infected with sporulated *Eimeria tenella* oocysts in group b showing ulceration and disruption of the mucosa (arrow head).

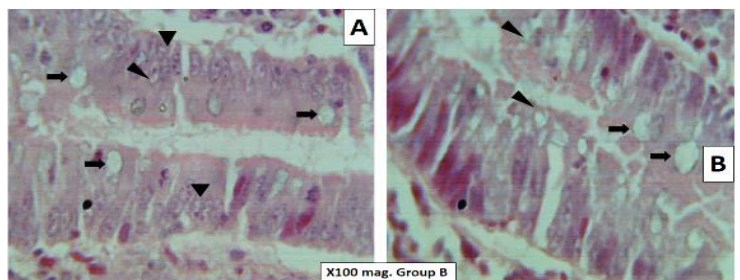


Figure VII: Photomicrographs of caeca from broiler chickens infected with sporulated *Eimeria tenella* oocysts in group B showing oocysts (arrow) and schizonts (arrow head).

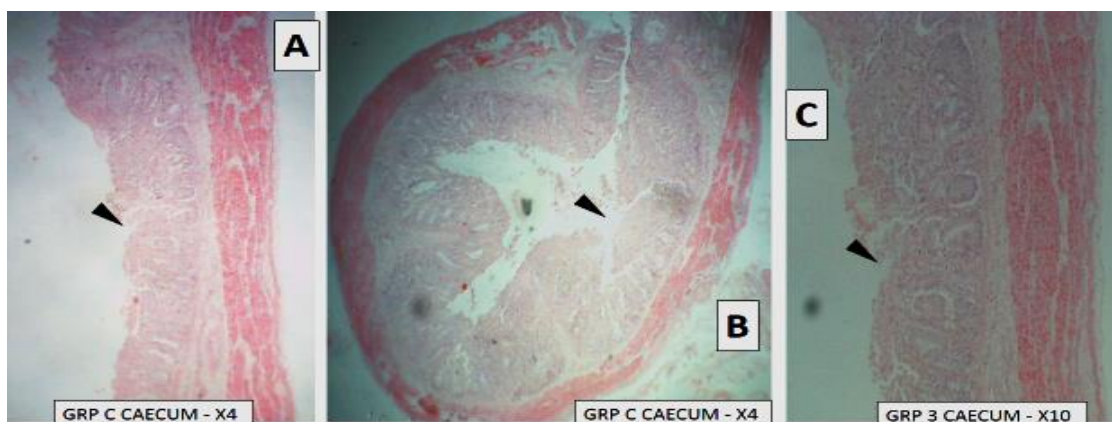

Figure VIII: Photomicrographs of caeca from broiler chickens infected with sporulated *Eimeria tenella* oocysts in group B showing erosion of the mucosa (arrow head A-C).

In group B, the liver sinuses and blood vessels were severely congested (Figure XIII). The multifocal aggregates of lymphocytes were depleted and they were decreased in numbers, and other areas of lymphoid aggregation were mostly hypoplastic (Figure XIII). There were few areas of degenerated hepatocyte around the portal triad and in the centrilobular area. In group C, the liver sinuses and blood

blood cells (Figure XV). All these were normal features in the avian spleen.

DISCUSSION

The finding of significantly lower activity score in group B, compared to the other groups, is consistent with previous

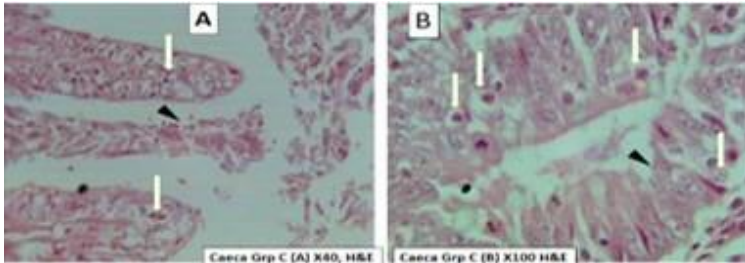


Figure IX: Photomicrographs of caeca from broiler chickens in group C developmental stages of Eimeria in the mucosa (arrow; A-B) and sloughing of epithelia (arrow head).

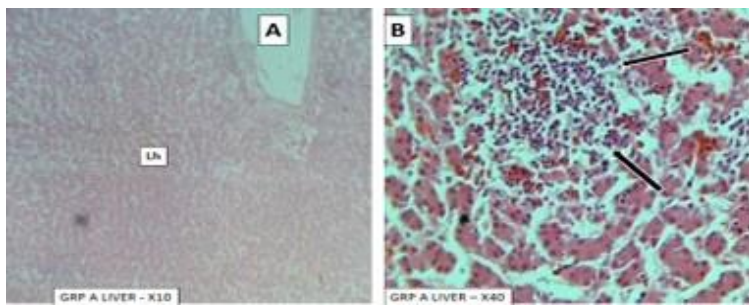


Figure X: Photomicrographs of broiler chickens Liver hepatocyte (Lh) arranged in cords in A and lymphoid nodule (arrow) in B.

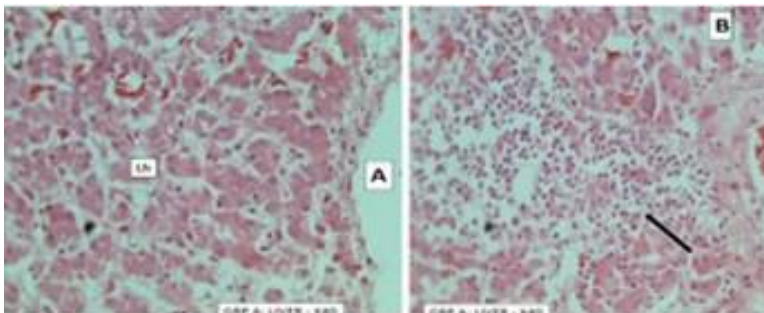


Figure XI: Photomicrographs of liver from broiler chickens in group A showing Liver hepatocyte (Lh) arranged in cords in A and lymphoid nodule (arrow) in B.

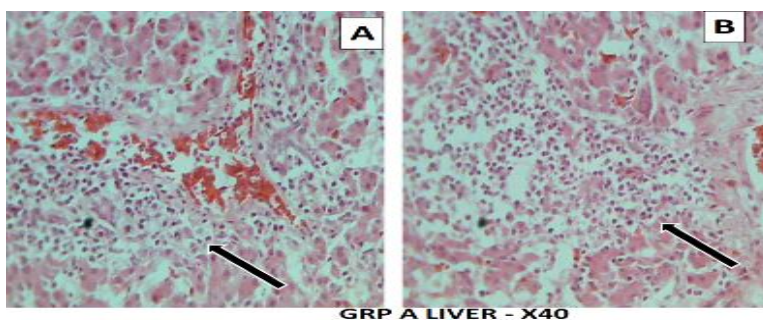


Figure XII: Photomicrographs of liver from broiler chickens in group A showing lymphoid nodule (arrow) in A and B.

vessels were moderately congested. The multifocal aggregates of lymphocytes were also depleted as in group B (Figure XIV). The spleen in the three groups (A - C), appeared normal and was covered by a thin connective tissue capsule. The white and red pulp percentages were essentially the same. The white pulp consists of lymphoid and non-lymphoid white blood cells. The red pulp is an open system and contains widely scattered lymphoid and non-lymphoid cells among red

studies on the activity of birds infected with Eimeria following treatment with amprolium (Campbell & Coles, 1986; Okonkwo *et al.*, 2019; Ukonu, *et al.*, 2023). The improved activity score in group C further highlights the positive effect of chemotherapy in enhancing survivability and performance in infected birds. Faecal scores in groups B and C were significantly lower than the control, with more severe symptoms observed in group B. This mirrors the pattern seen in activity scores and aligns with earlier findings that faecal

score is a useful indicator of morbidity (Campbell & Coles, 1986; Okonkwo *et al.*, 2019). By day 12 post-infection (PI), faecal score improvements in both groups suggest that coccidiosis is a self-limiting disease, as supported by Fakae (1987), Anosa *et al.* (2011); Okonkwo *et al.* (2019) and Ukonu, *et al.* (2023). Bleeding was observed around day 6 PI, coinciding with oocyst shedding from day 5 PI in both groups. Detectable *Eimeria* oocysts in the faeces of groups B and C by day 5 PI, was consistent with the report of Ngongeh *et al.* (2017), who observed oocysts as early as day 4 PI. As oocyst counts increased in groups B and C, corresponding declines in activity and faecal scores were observed, indicating worsening pathology. High oocyst loads were associated with extensive damage to the intestinal mucosa, which impaired digestive and absorptive functions, thereby reducing feed conversion efficiency. Minimizing infection doses remains

critical to limiting such damage (Ngongeh *et al.*, 2017). The peak and decline phases of oocysts count in groups B and C highlights the self-limiting nature of the disease. This reduction in oocyst count in group C demonstrates the efficacy of anticoccidial treatment, consistent with previous studies (McDougald & Fitz-Coy, 2008; Anosa *et al.*, 2011; Ngongeh *et al.*, 2017; Okonkwo *et al.*, 2019). However, the reduction in group C was unexpectedly poor, possibly due to emerging drug resistance in the local *Eimeria* strains. Histopathological findings revealed numerous oocyst schizonts and severe tissue damage in the caeca, coinciding with peak lesion severity and high oocyst counts. These changes were associated with the maturation of second-generation schizonts, leading to haemorrhage, glandular disruption, and mucosal necrosis (Chaiwat *et al.*, 2013; McDougald & Fitz-Coy, 2008; Ngongeh *et al.*, 2017). The faecal score drop by day 4 PI in

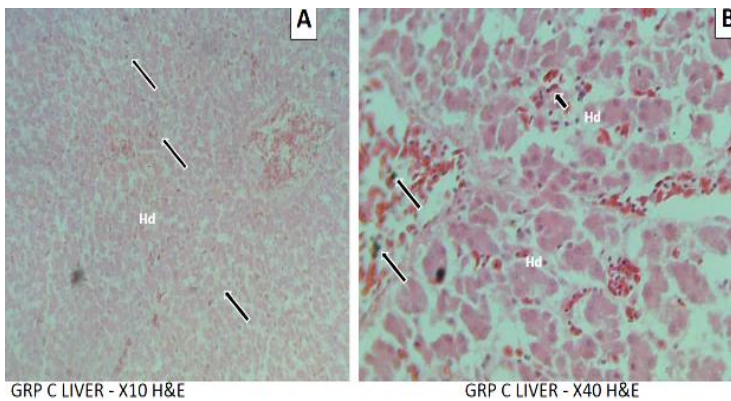


Figure XIII: Photomicrographs of liver from broiler chickens in group B showing disorganization (Hd) of hepatic cords (A), depletion of lymphoid nodule (arrow) in B and C.

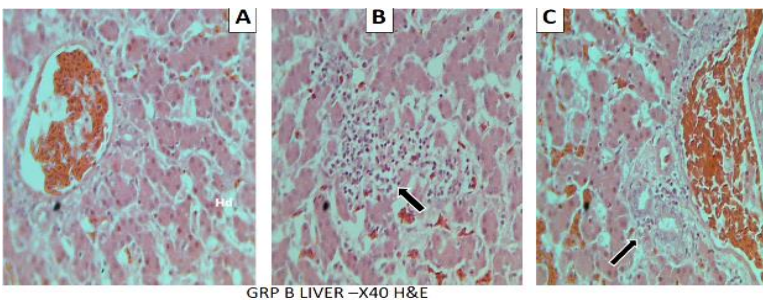


Figure XIV: Photomicrographs of liver from broiler chickens in group C showing disorganization (Hd) of hepatic cords and marked hemosiderosis (arrow) in A and B.

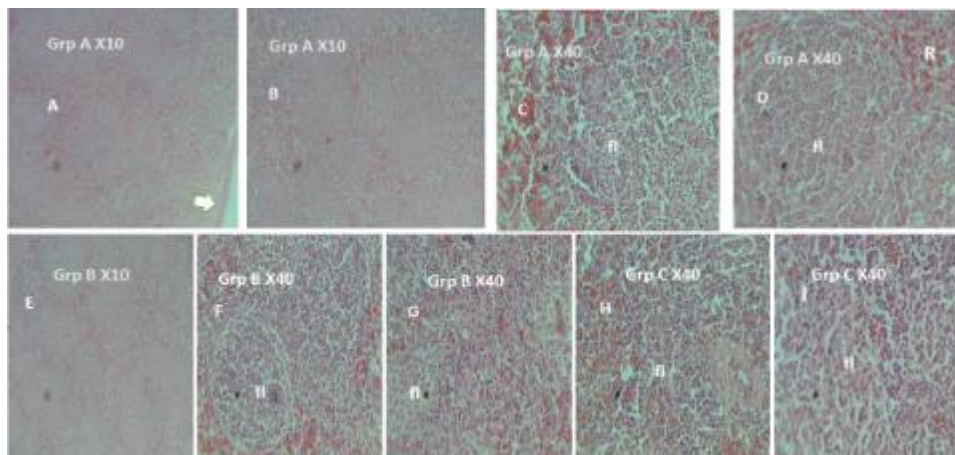


Figure XV: Photomicrographs of the spleen from broiler chickens in groups A to C showing normal splenic structure (A – D). Splenic capsule (arrow); follicle (fl); Red pulp (R). H&E

these groups may also reflect early mucosal damage and haemorrhage (Anosa *et al.*, 2011; Okonkwo *et al.*, 2019). However, group C recovered earlier and more effectively than group B, as reflected across several measured parameters, suggesting better resilience and response to treatment.

CONCLUSION

Coccidiosis is still a problem in the study area. The experimentally infected birds presented clinical signs, gross and histopathological changes in birds with the disease and these affect profitability of the industry/investment. Prophylactic treatment and good management geared towards prevention of the disease is advocated to prevent the loss of the biologic currency (nutrient-rich blood) and pathology (tissue injuries with attendant loss of function) seen in this study.

RECOMMENDATIONS

Farmers are advised to target prevention of the disease rather than managing the disease when it occurs. This is because if the disease is allowed to occur before treatment money will be spent yet there will be losses and unit cost of production per chicken will rise and profitability of the business will nose dive. It will also cause contamination of the poultry house and as well serve as source of infection to other poultry units. .

REFERENCES

- Abdu, P.A. & Musa, U. (2014). Textbook of Avian Medicine. 1st Ed. Zaria, Nigeria: P. A. Ndahi Printing. Pp. 1, 15,131 - 133.
- Anonymous. (2014). Umudike. <http://Wikipedia.org/wiki/umudike>. Accessed on 01/03/19 12.15noon.
- Anosa, G.N., Obetta, V.C., Okorie-Kanu, C.O. & Eze, J.I. (2011). Comparative efficacy of toltrazuril, amprolium and Embazine fort against mixed Eimeria species infection in broilers. *Nigerian Veterinary Journal*, 32(3), 214 - 217.
- Blake, D.P., Knox, J., Dehaeck, B., Huntington, B., Rathinam, T., Ravipati, V., Ayoade, S., Gilbert, W., Adebambo, A.O., Jatau, I.D., Raman, M., Parker, D., Rushton, J. & Tomley, F. M. (2020). Re-calculating the cost of coccidiosis in chickens. *Veterinary Research*. 51(1): 115.
- Campbell, T.W. & Coles E.H. (1986). Avian Clinical Pathology, 4th Ed. W. B. Saunders Company, Philadelphia. Pp. 279 – 300.
- Chaiwat, B., Meskerem, A., Nirat, G. & Montakan, V. (2013). Hematological, biochemical and histopathological changes caused by coccidiosis in chickens. *Kasetsart Journal of Natural Science*, 47, 238 – 246.
- Conway, D.P. & McKenzie, M.E. (2007). Poultry Coccidiosis: Diagnostic and Testing Procedures. 3rd Ed. Blackwell Publishing. Ames, IA, USA. Pp. 1 - 164.
- DeGussein, M. (2007). The 16th EU symposium on poultry nutrition. In: Coccidiosis in poultry; Review on diagnosis, control, prevention and interaction with overall gut health. Pp. 253 - 259.
- Elbahy, N.M., Mokhbattly, A.M. & Verginia, M.E. (2006). Comparative clinicopathological studies on garlic ethanolic extract and halofuginone compound against coccidiosis in chicken. *Journal of Veterinary Medicine*, 1(1), 1 - 15.
- Fakae, B.B. (1987). Veterinary Parasitology. Scotland: Bath press, Avon. Pp. 217 - 221.
- Long, P.L., Millard B.J., Joyner, L.P. & Norton, C.C. (1976). A guide to laboratory techniques used in the study and diagnosis of avian coccidiosis. *Folia Veterinary Latina*, 6: 200 – 217.
- McDougald, L.R., & Fitz-Coy, S.H. (2008). Coccidiosis. In: Diseases of Poultry, 12th Ed. Edited: Saif, Y.M., Fadly, A.M., Glisson, J.R., McDougald, L.R., Nolan, L.K., Swayne, D.E. Ames, IA: Blackwell Publishing Professional. Pp. 1068 – 1085.
- Morris, G.M. & Gasser, R.B. (2006). Biotechnological advances in the diagnosis of avian coccidiosis and the analysis of genetic variation in Eimeria. *Journal of Biotechnological Advances*, 24: 590 – 603.
- Ngongeh, L.A., Onyeabor, A., Nzenwata, E. & Samson, G.K. (2017). Comparative Response of the Nigerian Indigenous and Broiler Chickens to a Field Caecal Isolate of Eimeria Oocysts. *Hindawi Journal of Pathogens*, 2017: 1 – 9.
- Okonkwo, C.J., Ukonu C. E., Uwalaka E. C. & Okwara, N. (2019). An Evaluation of the Anticoccidial Potency of Some Commonly Used Anticoccidial Drugs in Broiler Industry in Abia State. *Journal of Global Veterinaria*, 21(2): 58 - 64.
- Petrie, A. & Watson, P. (1999). Statistics for Veterinary and Animal Science. 1st Ed. The Black well Science Ltd, United Kingdom. Pp. 90 – 115.
- Soulsby, E.J.L. (1982). Helminths Arthropods and Protozoa of Domesticated Animals. 7th Ed. Bailliere Tindall publishers, London, UK, Pp. 573 - 574.
- Ukonu, C. E., Egesi, Z. O., Ukonu, U. B., Daniel-Igwe, G., & Innocent, I. (2023). Comparative evaluation of cured turmeric powder for coccidial treatment in broiler chicken. In Centennial book of readings: Building a resilient root and tuber crops farming system for prosperity (pp. 53–58). NRCRI Publications.
- Wakenell, P.S. (2010). Hematology of chickens and turkeys. In: Veterinary haematology; Weiss, D.J., Wardrop,

K.J.: editors. 6th Ed. John Willey and Sons. Ames. Iowa, USA. Pp. 957–967.

Williams, R. B. (1999). A compartmentalised model for the estimation of the cost of coccidiosis to the world's chicken production industry. *International Journal for Parasitology*, 29(8), 1209–1229.