

## ASCARIDIASIS IN 18 WEEKS OLD PULLETS – A CASE REPORT

\***OGBONNA, I.J., UZOKA, U.H. & AKPAN, C.A.N.**

Department of Veterinary Medicine College of Veterinary Medicine, Michael Okpara University of Agriculture, Umudike, Nigeria.

\*Correspondence: [ogbonna.ijeoma@mouau.edu.ng](mailto:ogbonna.ijeoma@mouau.edu.ng); +2348037819135

### ABSTRACT

Parasitic infections in poultry production pose a significant challenge. *Ascaridia galli* is a nematode belonging to the phylum Nematoda that causes frequent infections along with significant morbidity and mortality in poultry birds, thereby leading to huge economic losses. *A. galli* has been detected in most of the species of poultry, including chickens, turkeys, geese, guinea fowl, and a wide variety of wild birds, with chicken being the main host. Clinical symptoms in birds include anorexia, ruffled feathers, weight loss, drop in egg production, anaemia, and diarrhoea, ultimately causing death. Upon post-mortem (PM) examination, partial or complete obstruction of the intestinal lumen alone or along with catarrhal to haemorrhagic enteritis was highly evident. Treatment with suitable anthelmintic and good management practices are the key components for the treatment, prevention and control of this disease.

**Keywords:** *Ascaridia galli*, economic loss, parasitic infections

### INTRODUCTION

Ascariasis is a parasitic disease caused by the nematode worm *Ascaridia galli* which infects the small intestine (Predilection site), but it can also be seen in the large intestine due to heavy infections as a result of the small intestine being severely affected. (Permin & Hansen, 1998). *Ascaridia galli* is a roundworm classified under the phylum Nematoda, class Chromadorea, order Ascaridida, and family Ascaridiidae (Tarbiat, 2018). It is characterized by a long, cylindrical body and exhibits sexual dimorphism. Males of *Ascaridia galli* are smaller typically measuring 50–76 mm in length and have a curved tail whereas females range from 72–116 mm and appear straight. They have three prominent lips and an oesophagus without a posterior bulb. Tail in male is equipped with ten pairs of papillae having alae. Notably, there is a round precloacal sucker present with a thick cuticular rim. The sub-equal spicule of the male varies in length from 1 to 2.4 mm. *Ascaridia galli* eggs are round with

smooth shells and are unsegmented when first laid. Eggs typically measures 73–92 µm in length and 45–57 µm in width (Soulsby, 1982; Permin & Hansen, 1998).

*Ascaridia* nematodes are commonly found in intestine of the birds (Permin and Hansen, 1998, Garadaghi, 2011). It is the most prevalent nematode species causing severe harm especially in the domestic fowl (*Gallus gallus domesticus*). The parasite has a direct life cycle. Infectious eggs hatch in the duodenum of the suitable hosts, and the juvenile larvae initially inhabit the caudal part of the duodenal lumen after hatching and subsequently penetrating the mucosa, leading to haemorrhages. Juvenile worms remain in the duodenal lumen until they reach a mature stage after 28–30 days (Permin & Hansen, 1998). The most significant predisposing factors for Ascariasis include young age, pre-infection with coccidiosis, and deficiency of vitamin A and protein in the diet (Permin & Hansen, 1998).



**Figure I: A section of the birds in battery cage showing poor biosecurity, dirty dropping boards and floor and feather accumulation**

Ascariasis can be controlled by regular anthelmintic treatment. However, frequent administration of anthelmintics can lead to their resistance (Salam, 2015). Since *Ascaridia galli* eggs require moisture for their survival, it is very important to keep the bedding dry and replacing it regularly with the fresh bedding in order to prevent the infection. All these preventive measures hold greater significance particularly to prevent the young birds from getting infected (Jacobs *et al.*, 2003). Previously, several researchers have documented findings associated with *A. galli* infection. These include the detection of nematode eggs in the faeces and the presence of large white worms in the poultry droppings of the bird. The primary treatment for *Ascaridia galli* includes anthelmintic drugs, mainly piperazine.

### CASE HISTORY

Two carcasses of 18 weeks brown pullets belonging to Asiegbu Enyiazu Farm Nigeria Limited in Amuzuoro, Abia State, Nigeria, with a flock size of 1880 pullets kept in battery cages were observed during a routine veterinary visit on 7<sup>th</sup> September, 2024. Detailed history was noted and the dead birds were submitted for necropsy. Clinical observations and necropsy examinations were carried out. Mortality and morbidity rate of 0.1% respectively was recorded during a period of 3 days.

### CLINICAL OBSERVATION

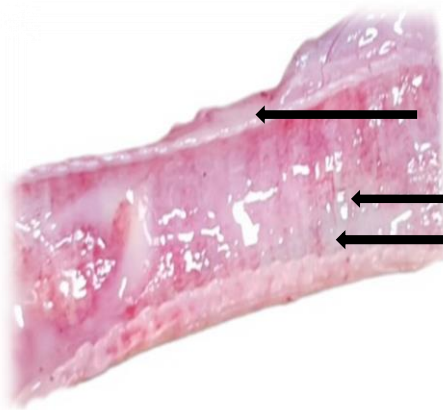
The birds weighing about 1.4kg live weight were duly vaccinated and deworming was done at 10 weeks of age when they were still raised under deep litter management. They were brooded in deep Litters for 12 weeks before being transferred to battery cages (Figure I). They were fed With Chikun® Grower Feed. Clinical observations made in the flock include drop in feed intake, depression, sunken eyes and ruffled feathers. There were poor biosecurity measures such as no foot dip, dirty environment and the attendants were wearing slippers.

### GROSS LESION

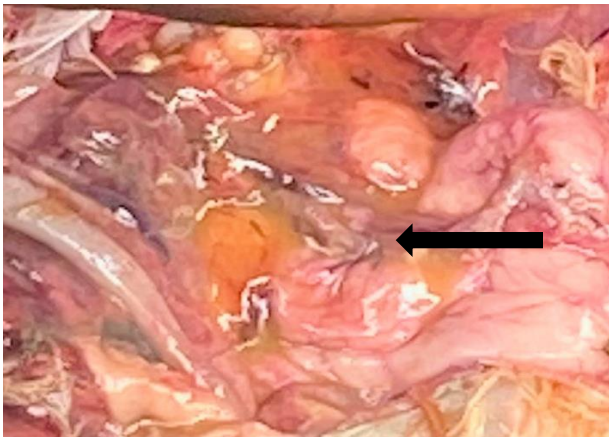
Necropsy revealed heamorrhagic trachea containing mucoid exudate (Figure II), egg yolk peritonitis (Figure III) and heavy worm infestation in the duodenum (Figure IV). The worms were collected washed in 1× Phosphate Buffer saline PBS is a hypertonic solution and sent to Department of Parasitology and Entomology, College of Veterinary Medicine, MOUAU for identification. It was identified as *Ascaridia galli* (Figure V).

### DIAGNOSIS

Tentative diagnosis of ascariasis was made based partial occlusion of intestinal lumen by large number of adult worms (Figure IV). Differential diagnoses also considered due to secondary/concurrent bacterial infection were colibacillosis due to egg yolk peritonitis and chronic respiratory disease (CRD) due to mucoid exudate and heamorrhages on the trachea. The diagnosis of Ascariasis was confirmed by identification of the worm. The worms were stout and densely white. The males were short in length 50-76 mm while the female were longer (72-116 mm). The male worms were smaller in diameter than the female worms and have posterior end that is curved ventrally. The worms' oesophagus has no posterior bulb but have circular precloacal suckers with thick cuticular rim and the spicules are sub equal.



**Figure II: A section of the hemorrhagic tracheitis showing mucoid exudate.**



**Figure III: Fibrinous exudate and yolk material.**



**Figure IV: Duodenum opened; numerous adult *A. galli* causing partial obstruction**



**Figure V: *Ascaridia galli***

## DISCUSSION

More than thirty helminthes have been reported in chicken. Among these *Ascaridia galli* is the most common parasite (Shifaw *et al.*, 2021). Ascariasis is a parasitic disease caused by the nematode worm *Ascaridia galli* with the small intestine as its Predilection site as seen in this case but it can also be seen in the large intestine due to heavy infections as a result of the small intestine being severely affected. (Permin and Hansen, 1998).

Although, *A. galli* has long been known to occur in chickens under a variety of housing conditions worldwide, the parasite was generally less prevalent when laying hens were kept in conventional battery cages separate from their droppings (Höglund *et al.*, 2023). Due to high fecundity of *A. galli* and weak response of the chicken host, the intensity of infection has increased over time (Wongrak *et al.*, 2015). Parasitism is a challenge, especially in intensive production, as more birds per unit area means a greater risk of contamination. The highly resistant *A. galli* eggs are excreted in host faeces and they remain viable under the conditions of manure accumulation under cages, moisture sources, water line leaks, absence of footbaths/dedicated boots, vermin control, and movement history (deep litter to cages at 12 weeks), would lead to environmental egg survival which later develop (embryonate *in ovo*) into eggs with an infective larva (Tarbiat *et al.*, 2018; Shifaw *et al.*, 2022). More than 88% of *A. galli* eggs are deposited in host faeces and they complete their development after only one to two weeks under optimal conditions (Tarbiat *et al.*, 2015; Rahimian *et al.*, 2016). Although many ascarid eggs are destroyed within a few months, a small proportion (up to 3%) can survive for up to two years (Thapa *et al.*, 2017), encouraging accumulation of infectious eggs in the environment and reinfection. After ingestion, the larvae hatch from the eggs, and penetrate the intestinal mucosa as part of their development process (Ferdushy *et al.*, 2012) causing damages such as irritation and inflammation to the mucosa (Pleidrup *et al.*, 2014).

Some larvae do reappear in the intestinal lumen and become adult worms, which reach sexual maturity after about five weeks and start excreting the parasite's eggs for several months if not expelled (Stehr *et al.*, 2018).

Also, the conditions of dirty dropping boards and floor and feather accumulation and no presence of foot dips prevailing in this poultry house (poor biosecurity measure) predisposes the birds to secondary bacterial infection such as colibacillosis and salmonellosis. Poor air quality due to high level of ammonia from faecal droppings damages the cilia lining respiratory tract leading to a higher risk of chronic respiratory disease (CRD). When the worm burden is high, there would be loss of appetite, diarrhoea and mechanical intestinal obstruction, which in turn can lead to reduced nutrient absorption and depletion of fat reserves in the liver (Das *et al.*, 2010; Sharma *et al.*, 2018; Torres *et al.*, 2019). Severe infections reduce weight gain and may even lead to increased mortality (Hinrichsen *et al.*, 2016). Flocks of laying hens on litter usually remain infected to some extent with drop in egg production and sometimes even increase with age until the end of the production cycle (Zloch *et al.*, 2018).

One of the most effective methods of controlling ascarids is to treat the birds with an anthelmintic (Tarbiat *et al.*, 2016). Several drugs, including benzimidazoles (fenbendazole and flubendazole), imidazothiazoles (levamisole and pyrantel) and macrocyclic lactones (ivermectin), have been shown to be effective against *A. galli* (Feyera *et al.*, 2022). The farmer was encouraged to treat with Ivermectin (center ivemec 1%) due to cost. Ivermectin at a dosage of 0.25mg/kg per os (1ml per 5 liters of drinking) (Arisova, 2020) was chosen as the choice of drug also due to its broad-spectrum effect against intestinal nematodes such as *Ascaridia galli* and many ectoparasites. The withdrawal period is 14 days and birds were in pre-lay with no eggs entering the food chain. Ivermectin have a unique pharmacological properties and mechanisms of action. It binds to glutamate-gated chloride channels in the parasite's nervous system, disrupting neurotransmission and causes paralysis and death of the worm (Atif *et al.*, 2017). The farmer was encouraged not only to treat but also to put preventive measures in place such as routine complete cleaning of poultry houses as well as periodic screening of the birds for the presence of worms (Kalu *et al.*, 2022). 14 days post treatment, with improved biosecurity measures in the farm, the birds started to lay eggs.

## CONCLUSION

*Ascaridia galli* is the largest gut-dwelling helminth of chickens, which confers adverse effects on meat and egg production; thus, on the animal protein supply and the economy. Thus, *A. galli* is on the rise and is now increasingly found in laying hens kept for commercial egg production. The parasite thus appears to be an escalating problem that

requires the increased attention of researchers, who still have much to learn about improving control strategies.

Efforts need to be made to develop and validate evidence-based control approaches that take advantage of diagnostics and combine them with the use of anthelmintics, without ignoring the risk of resistance development.

**ETHICS & PERMISSIONS:** All procedures performed in this study involving human participants were conducted ethically according to ethical standards of National Research Committee. Informed consent was obtained from all individual participants included in this study.

## REFERENCES

- Arisova, G. B. (2020). Efficacy of Ivermectin-based drugs against ectoparasites in broiler chicken. *World Veterinary Journal*, 10(2):160-164.
- Atif, M, Estrada-Mondragon, A., Nguyen, B., Lynch, J. W. & Keramidias, A. (2017). Effects of glutamate and ivermectin on single glutamate-gated chloride channels of the parasitic nematodes. *PLoS Pathology*, 13(10), e1006663.
- Das, G., Kaufmann, F., Abel, H. & Gauly, M., (2010). Effect of extra dietary lysine in *Ascaridia galli*-infected grower layers. *Veterinary Parasitology*, 170, 238–243.
- Ferdushy, T., Nejsun, P., Roepstorff, A., Thamsborg, S.M. & Kyvsgaard, N.C., (2012). *Ascaridia galli* in chickens: intestinal localization and comparison of methods to isolate the larvae within the first week of infection. *Parasitology Research*, 111, 2273–2279.
- Feyera, T., Sharpe, B., Elliott, T., Yesuf, A., Ruhnke, I., Walkden-Brown, S.W., Shifaw, A. Y., Ruhnke, I. & Walkden-Brown, S.W., (2022). Anthelmintic efficacy evaluation against different developmental stages of *Ascaridia galli* following individual or group administration in artificially trickle-infected chickens. *Veterinary Parasitology*, 301.
- Garadaghi Y. (2011). Identification of immunogenic relevant antigens in the excretory-secretory (ES) products of *Ascaridia galli* larvae. *Advances in Environmental Biology*, 5(6), 1120-1126.
- Höglund, J., Das, G., Tarbiat, B., Geldhof, B., Jansson, D.S., & Gauly, M. (2023). *Ascaridia galli* - An old problem that requires new solutions. *International Journal for Parasitology: Drugs and Drug Resistance*. 23, 1-9.
- Hinrichsen, L.K., Labouriau, R., Engberg, R.M., Knierim, U. & Sørensen, J.T., (2016). Helminth infection is associated with hen mortality in Danish organic egg production. *Veterinary Record*, 179, 196.
- Jacobs, R.D., Hogsette, J.A. & Butcher, J. D. (2003). Nematode parasites of poultry (and where to find them).

- The Institute of Food and Agricultural Sciences (IFAS) series PS18, University of Florida, USA. p. 1-10.
- Kalu, E., Akporube, K. A., Uwalaka, E., Ukwueze, C. S. Ani, N. V. & Edward, I. G. (2022). Intestinal cestode infection of Raillietina species in a 9 weeks old broilers in Umuahia. *Journal of sustainable Veterinary and Allied Sciences*, 3(2), 123-125.
- Permin, A & Hansen, J. W. (1998). Epidemiology, diagnosis and control of poultry parasites. FAO Animal health manual, pp. 24.
- Pleidrup, J., Dalgaard, T.S., Norup, L.R., Permin, A., Schou, T.W., Skovgaard, K., Vadekær, D.F., Jungersen, G., Sørensen, P. & Juul-Madsen, H.R., (2014). *Ascaridia galli* infection influences the development of both humoral and cell-mediated immunity after Newcastle Disease vaccination in chickens. *Vaccine*, 32, 383–392.
- Rahimian, S., Gaulty, M. & Das, G., (2016). Embryonation ability of *Ascaridia galli* eggs isolated from worm uteri or host faeces. *Veterinary Parasitology*, 215, 29–34.
- Salam, S.T. (2015). Ascariasis in backyard chicken-prevalence, pathology and control. *International Journal of Recent Scientific Research*, 6(4), 3361-3365.
- Sharma, N., Hunt, P.W., Hine, B.C., Sharma, N.K., Chung, A., Swick, R.A. & Ruhnke, I., (2018). Performance, egg quality, and liver lipid reserves of free-range laying hens naturally infected with *Ascaridia galli*. *Poultry Science*, 97, 1914–1921.
- Shifaw, A., Feyera, T., Elliott, T., Sharpe, B., Walkden-Brown, S.W. & Ruhnke, I., 2021. Comparison of the Modified McMaster and Mini-FLOTAC methods for the enumeration of nematode eggs in egg spiked and naturally infected chicken excreta. *Veterinary Parasitology*, 299, 109582.
- Shifaw, A., Feyera, T., Elliott, T., Sharpe, B., Ruhnke, I. & Walkden-Brown, S.W., 2022. Method optimisation for prolonged laboratory storage of *Ascaridia galli* eggs. *Veterinary Parasitology*, 309, 109758.
- Soulsby, E. J. L. (1982). Helminths, Athropods and Protozoa of Domesticated Animals. Edn 7, Baillière Tindall, London, UK, 163-165.
- Stehr, M., Sciascia, Q., Metges, C.C., Gaulty, M. & Das, G., (2018). Co-expulsion of *Ascaridia galli* and *Heterakis gallinarum* by chickens. *International Journal of Parasitology*, 48, 1003–1016.
- Tarbiat, B., Jansson, D.S. & Höglund, J., (2015). Environmental tolerance of free-living stages of the poultry roundworm *Ascaridia galli*. *Veterinary Parasitology*, 209, 38–42.
- Tarbiat, B., Jansson, D.S., Tyden, E. & Höglund, J. (2016). Comparison between anthelmintic treatment strategies against *Ascaridia galli* in commercial laying hens. *Veterinary Parasitology*, 226, 109–115.
- Tarbiat, B., Rahimian, S., Jansson, D.S., Halvarsson, P. & Höglund, J. (2018). Developmental capacity of *Ascaridia galli* eggs is preserved after anaerobic storage in faeces. *Veterinary Parasitology*, 255, 38–42.
- Thapa, S., Thamsborg, S.M., Meyling, N.V., Dhakal, S. & Mejer, H., (2017). Survival and development of chicken ascarid eggs in temperate pastures. *Parasitology*, 144.
- Torres, A.C.D., Costa, C.S., Pinto, P.N., Santos, H.A., Amarante, A.F., Gómez, S.Y.M., Resende, M., Martins, N.R. & da S., (2019). An outbreak of intestinal obstruction by *Ascaridia galli* in broilers in Minas Gerais. *Revision Brasileira Ciênciã Avícola*, 21, 10–13.
- Wongrak, K., Gaulty, M. & Das, G., (2015). Diurnal fluctuations in nematode egg excretion in naturally and in experimentally infected chickens. *Veterinary Parasitology*, 208, 195–203.
- Zloch, A., Kuchling, S., Hess, M. & Hess, C., (2018). Influence of alternative husbandry systems on postmortem findings and prevalence of important bacteria and parasites in layers monitored from end of rearing until slaughter. *Veterinary Record*, 182.